

## Surgical resection of a giant mass pushing the boundaries of the chest wall: An Askin's tumor

*Göğüs duvarının sınırlarını zorlayan dev kitlenin cerrahi rezeksiyonu: Askin tümörü*

Güntüğ Batihan , Şeyda Örs Kaya 

Department of Thoracic Surgery, University of Health Sciences, Izmir Dr. Suat Seren Chest Diseases and Surgery Hospital SUAM, Izmir, Türkiye

### ABSTRACT

Intrathoracic masses may arise from the chest wall, mediastinum, pleura, and pulmonary parenchyma. Primary malignant tumors of the chest wall and pleura usually present with chest pain; however, the tumor may sometimes remain asymptomatic, until it grows large enough to cause compression-related symptoms. Herein, we present a 35-year-old female case with a giant intrathoracic mass. The patient was diagnosed with an Askin's tumor and underwent extended surgical resection.

**Keywords:** Askin's tumor, chest wall, primitive neuroectodermal tumor, surgery.

A primitive neuroectodermal tumor (PNET) is a group of highly malignant tumor which develops from primitive nerve cells or soft tissue. It was first described by Stout in 1918<sup>[1]</sup> as a small, round-cell group exhibiting rosettes formation. Askin et al.<sup>[2]</sup> reported a case series of 20 patients and described the PNET group originating from the thoracic region. It develops almost always from the soft tissues of the chest wall and presents with large intrathoracic masses.

Askin's tumors mostly occur in pediatric or early adult age and are related to poor prognosis. Although there is no consensus regarding its treatment, as it is one of the rare malignant diseases, multimodal treatment including surgery, chemotherapy, and radiotherapy is recommended.<sup>[3]</sup>

In this article, we present an adult female patient with an intrathoracic gross mass and discuss our

### ÖZ

İntratorasik kitleler göğüs duvarı, mediastinum, plevra veya akciğer parankiminden köken alabilir. Göğüs duvarı ve plevranın primer malign tümörleri sıklıkla göğüs ağrısı ile seyretmekle birlikte, kimi zaman büyük boyutlara ulaşana dek asemptomatik olarak da kalabilmektedir. Bu yazıda dev intratorasik kitle tespit edilen 35 yaşında bir kadın olgu sunuldu. Hastaya Askin tümörü tanısı konularak, genişletilmiş cerrahi rezeksiyon yapıldı.

**Anahtar sözcükler:** Askin tümörü, göğüs duvarı, primitif nöroektodermal tümör, cerrahi.

multimodal treatment approach including radical surgical resection.

### CASE REPORT

A 35-year-old female presented a three-month history of cough, dyspnea, and right-sided chest pain. The patient was an active smoker (10 pack-year), and her medical history was unremarkable, except for cesarean operation. A chest radiogram showed an opacity covering the lower half of the right hemithorax. Subsequent thoracic computed tomography (CT) with an intravenous contrast agent revealed a 19×18-cm intrathoracic giant mass. Chest magnetic resonance imaging (MRI) was planned to evaluate possible invasions of the mass to the chest wall, mediastinum, and diaphragm. On MRI, there was no invasion in the mediastinum, diaphragm, and pulmonary parenchyma. However, both thoracic CT and MRI showed the

**Corresponding author:** Güntüğ Batihan.

E-mail: gbatihan@hotmail.com

Doi: 10.5606/tgkdc.dergisi.2023.20761

**Received:** September 14, 2020

**Accepted:** November 30, 2020

**Published online:** January 30, 2023

**Cite this article as:** Batihan G, Örs Kaya Ş. Surgical resection of a giant mass pushing the boundaries of the chest wall: An Askin's tumor. Turk Gogus Kalp Dama 2023;31(1):131-135. doi: 10.5606/tgkdc.dergisi.2023.20761.

©2023 All right reserved by the Turkish Society of Cardiovascular Surgery.

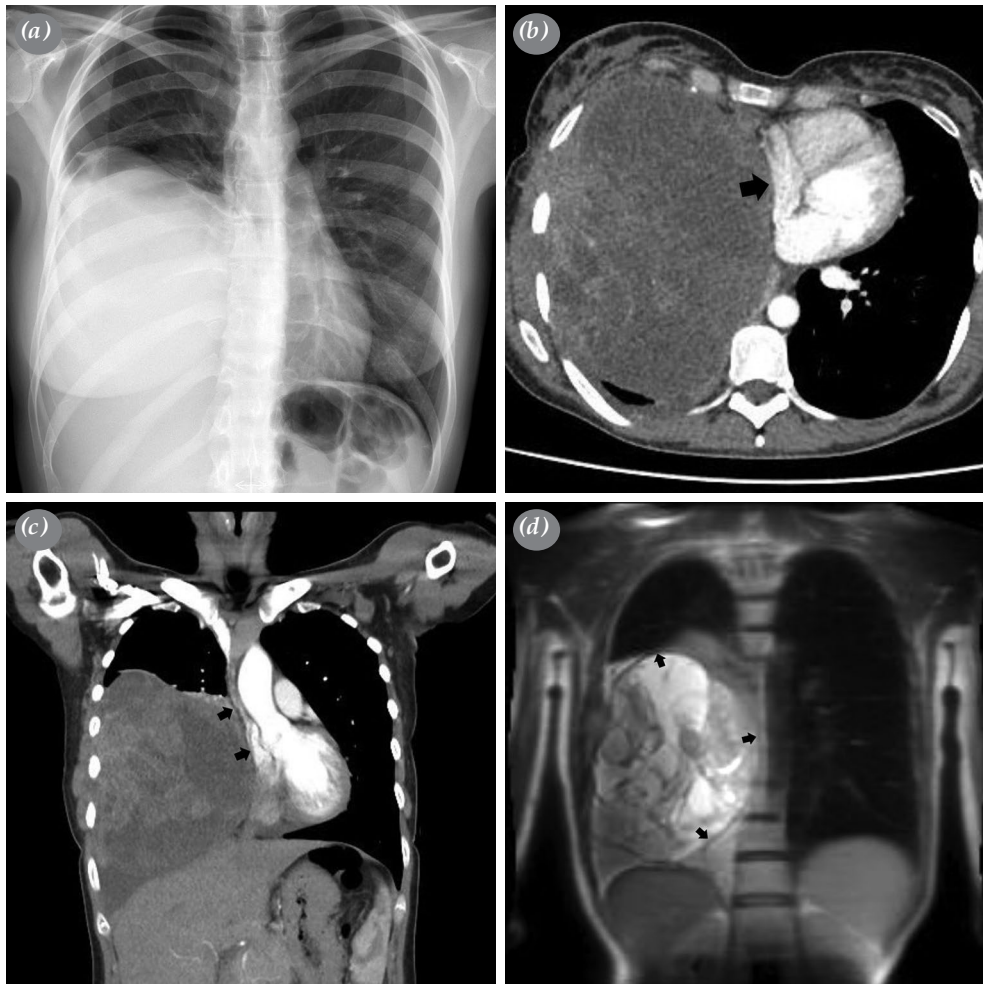

This is an open access article under the terms of the Creative Commons Attribution-NonCommercial License, which permits use, distribution and reproduction in any medium, provided the original work is properly cited and is not used for commercial purposes (<http://creativecommons.org/licenses/by-nc/4.0/>).

destruction of the sixth rib adjacent to the tumor. In addition to the thoracic CT and MRI, positron emission tomography (PET)/CT was performed which revealed no distant metastasis. Due to the compression of the mass, the right lung was totally atelectatic, and PET/CT, thoracic CT, and MRI could not provide any data on lung parenchyma.

Transthoracic fine-needle aspiration biopsy was planned; however, the patient refused the procedure. The surgical operation was planned based on two indications. First, the patient had severe respiratory symptoms due to the compression of the tumor on the lung and atrium. Second, there was still no diagnosis, and pathological sampling was needed.

Therefore, right-sided posterolateral thoracotomy was planned. During exploration, the gross tumor originating from the chest wall was seen. The tumoral lesion was excised with unblock chest wall resection, included partial fifth and sixth rib excision, leaving behind a macroscopically 2-cm tumor negative margin. However, after the removal of the giant tumor, multiple metastatic lesions were observed on the atelectatic lung parenchyma. Multiple wedge resections were performed. The defect on the chest wall was repaired with a polypropylene mesh. The procedure was completed after the chest tube placement. Small round blue cells were observed in the histopathological analysis and cytokeratin,



**Figure 1.** (a) Right-sided opacity is seen on chest radiogram. (b) Chest computed tomography revealed a right-sided giant intrathoracic mass compressing to pulmonary parenchyma and right atrium (arrow). (c) Coronal computed tomography plane evaluating the mediastinal shift caused by the compression of the giant mass (arrows). (d) According to the thoracic magnetic resonance imaging, there is no invasion in the mediastinum, diaphragm, and pulmonary parenchyma (arrows).

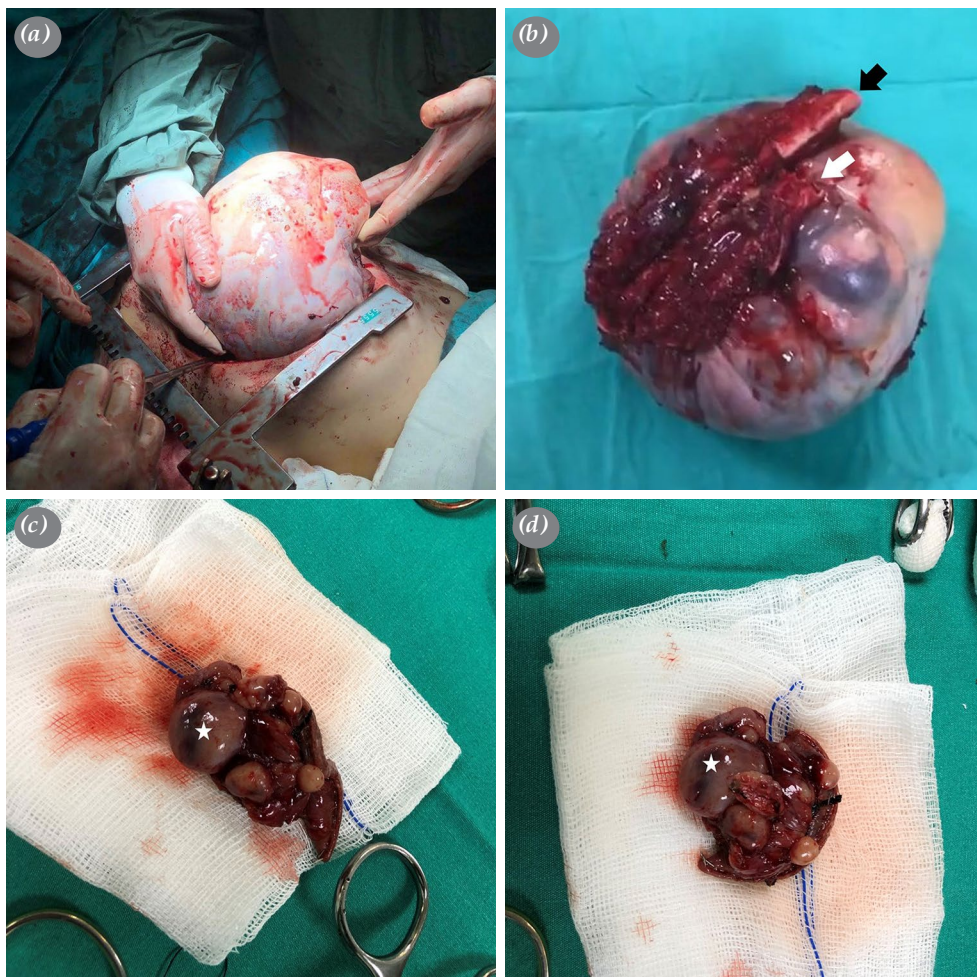
vimentin, and CD99 positivity was detected in the immunohistochemical examination. Therefore, the patient was diagnosed with a PNET of the chest wall (Askin's tumor).

After the operation, adjuvant chemotherapy was planned, and alternating cycles of vincristine, doxorubicin, cyclophosphamide, and etoposide treatment was scheduled. Our patient is currently at the end of the second postoperative year and is still alive. However, local recurrence was observed after 18 months from the surgery, and the treatment of the patient still continues.

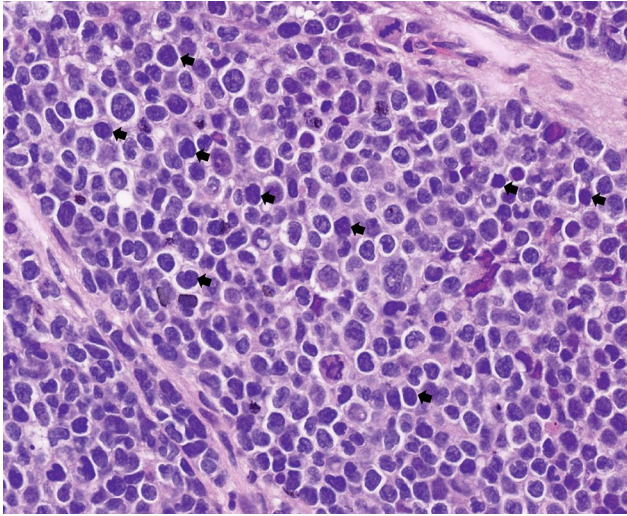
## DISCUSSION

Askin's tumor was firstly reported by Askin et al.<sup>[2]</sup> as a subset of the peripheral PNETs.<sup>[2]</sup> These tumors are very rare and presented in the literature as case reports.<sup>[3-5]</sup> Although it is often seen in children and young adults, it can be observed as rare cases in adults. Patients usually presented with chest pain, dyspnea, cough, fever, and weight loss. Patients may remain asymptomatic, until compression-related symptoms appear.

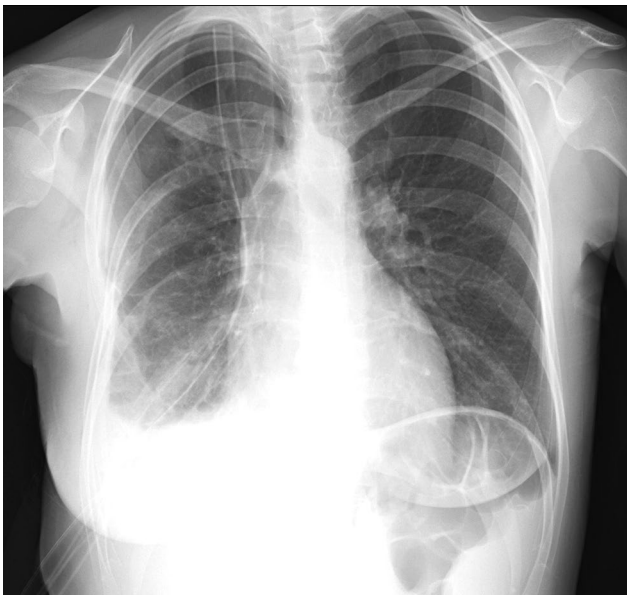Thoracic CT findings include heterogeneous attenuations and multiple areas of cystic degenerations.



**Figure 2.** (a) Intraoperative image of the intrathoracic giant mass. The tumor can only be removed by partial resection of the two ribs. (b) White and black arrows indicate the fifth and sixth ribs. According to the pathological examination, the tumor originates from the chest wall including the fifth and sixth ribs. Surgical margins are negative on these ribs in the pathological examination. (c) Parenchymal cystic metastasis is observed after the removal of the tumor, and multiple wedge resections are performed. This resection material belongs to the upper lobe and the asterisk indicates cystic metastatic lesion. (d) Another wedge resection is performed in the middle lobe. Asterisk indicates cystic metastatic lesion.



**Figure 3.** Small round blue cells (the most typical ones for pathological diagnosis are indicated by arrows) are observed in the histopathological analysis (H&E, ×400).



**Figure 4.** Postoperative chest radiogram showing the patient's symptoms in the preoperative period which regressed dramatically as the right lung began to participate in respiration and the compression on the mediastinum ended.

The mass is usually greater than 5 cm, and erosion or pathological fracture can be observed in the neighboring ribs.<sup>[5]</sup> Ultrasound or CT-guided transthoracic needle aspiration biopsy can be preferred to achieve a diagnostic sample. In our case, the patient had severe dyspnea due to the compression of the mass on the atrium and lung and, therefore, surgical resection

was preferred, although there was no preoperative pathological diagnosis.

Although there is no consensus in the literature, multimodal treatment, including surgical resection, is recommended. R0 resection has been shown to be associated with prolonged overall and disease-free survival. Therefore, radical surgical resections can be preferred to achieve a clear margin.

Chemotherapy can be also applied as neoadjuvant or adjuvant, and neoadjuvant therapy can reduce the size of the tumor, making the surgical procedure safer and increase the chance of R0 resection.<sup>[6]</sup> Although there are no standard chemotherapy regimens for Askin's tumor, the chemotherapy regimen used for Ewing sarcoma consisted of 12 cycles of vincristine, actinomycin D, cyclophosphamide and doxorubicin can be applied.<sup>[5,6]</sup>

Radiotherapy is also used for the local control of the primary lesion, particularly the presence of the residual tumor after surgery. Although there is no specific recommendation for Askin's tumors in the literature, the lateral resection margin of 2-cm is considered safe for low-grade tumors and 4 cm for high-grade tumors.<sup>[4-6]</sup> In our case, a macroscopic chest wall resection with a margin of 2 cm was performed. Due to the presence of parenchymal metastases resection margins were not extended.

In general, this tumor group has aggressive behavior, and local recurrences and distant metastases are frequently encountered, and five-year survival rates range from 14 to 60%.<sup>[6]</sup> In addition, positive or close surgical margin, large tumor size, presence of pleural effusion, and poor response to chemotherapy were related to poor prognosis.<sup>[6]</sup>

In conclusion, Askin's tumor should be kept in mind in the differential diagnosis in intra-thoracic pathologies, and multimodal treatment including radical surgical resection should be planned in these patients.

**Patient Consent for Publication:** A written informed consent was obtained from the patient.

**Data Sharing Statement:** The data that support the findings of this study are available from the corresponding author upon reasonable request.

**Author Contributions:** Idea/concept: G.B.; Design: G.B., S.O.K.; Control/supervision: S.O.K.; Analysis and/or interpretation: G.B., S.O.K.; Literature review: G.B.; Writing the article: G.B.; Critical review: S.O.K.; References: G.B.

**Conflict of Interest:** The authors declared no conflicts of interest with respect to the authorship and/or publication of this article.

**Funding:** The authors received no financial support for the research and/or authorship of this article.

## REFERENCES

1. Stout AP. A tumor of the ulnar nerve. Proc NY Pathol Soc 1918;18:2-12.
2. Askin FB, Rosai J, Sibley RK, Dehner LP, McAlister WH. Malignant small cell tumor of the thoracopulmonary region in childhood: A distinctive clinicopathologic entity of uncertain histogenesis. Cancer 1979;43:2438-51. doi: 10.1002/1097-0142(197906)43:6<2438::aid-cncr2820430640>3.0.co;2-9.
3. Katsenos S, Nikopoloulou M, Kokkonouzis I, Archondakis S. Askin's tumor: A rare chest wall neoplasm. Case report and short review. Thorac Cardiovasc Surg 2008;56:308-10. doi: 10.1055/s-2007-989342.
4. Kaçar F, Yağcı A, Önel A. Askin tümörü. Turk Gogus Kalp Dama 2001;9:115-7.
5. Benbrahim Z, Arifi S, Daoudi K, Serraj M, Amara B, Benjelloun MC, et al. Askin's tumor: A case report and literature review. World J Surg Oncol 2013;11:10. doi: 10.1186/1477-7819-11-10.
6. Laskar S, Nair C, Mallik S, Bahl G, Pai S, Shet T, et al. Prognostic factors and outcome in Askin-Rosai tumor: A review of 104 patients. Int J Radiat Oncol Biol Phys 2011;79:202-7. doi: 10.1016/j.ijrobp.2009.10.039.