

## Bronchial sleeve resections

### *Bronşiyal sleeve rezeksiyonlar*

Muhammet Sayan , Abdullah İrfan Taştepe 

Department of Thoracic Surgery, Gazi University Faculty of Medicine, Ankara, Türkiye

#### ABSTRACT

Although bronchial sleeve resections were previously defined as an alternative technique to pneumonectomy for patients with limited pulmonary reserve, currently these resections are applied as a standard even in patients having normal pulmonary capacity. Pneumonectomy, itself, is a disease, and sleeve lobectomies can be performed without compromising oncological principles and without causing significant morbidity and mortality. In parallel with the developments in surgical techniques, bronchial sleeve resections can be performed by videothoracoscopic and robotic surgeries. Major complications in sleeve lobectomies are bronchial dehiscence, bronchopleural fistulas, and broncho-arterial fistulas. Late complications are bronchial stenosis and tumor recurrence.

**Keywords:** Anastomosis, bronchial sleeve lobectomy, sleeve resection.

The term bronchial sleeve resection describes the cutting of the both main bronchus and lobe bronchus with or without resection of lobar lung tissue and, anastomosis of tumor-free bronchial ends. Procedures which involve the resection of the lobar parenchyma are called bronchial sleeve lobectomy (BSL).<sup>[1,2]</sup> While BSL has emerged as an alternative technique for pneumonectomy in patients with impaired pulmonary function, it has become a standard resection, even when the respiratory capacity is normal in suitable indications, and it has reached the rate of 13% of all pulmonary resections.<sup>[3]</sup>

Historically, the first case of BSL was reported by Thomas<sup>[4]</sup> in 1947, series on this subject were published in the following years and BSL was described in textbooks with its standard indications and

#### ÖZ

Bronşiyal sleeve rezeksiyonlar önceleri pulmoner rezervi kısıtlı hastalarda pnömonektomiye alternatif bir teknik olarak tanımlanmışken, günümüzde bu rezeksiyonlar normal pulmoner kapasiteye sahip hastalarda dahi standart olarak uygulanmaktadır. Pnömonektomi başlı başına bir hastalık olup, sleeve lobektomiler onkolojik ilkelerden ödün vermeden ve önemli morbidite ve mortaliteye neden olmadan yapılabilmektedir. Cerrahi tekniklerdeki gelişmelere paralel olarak videotorakoskopik ve robotik cerrahi ile bronşiyal sleeve rezeksiyonlar yapılabilmektedir. Sleeve lobektomilerde başlıca komplikasyonlar bronşiyal ayrılma, bronkoplevral fistül ve bronkoarteriyel fistüldür. Geç komplikasyonlar ise, bronşiyal darlık ve tümör nüksüdür.

**Anahtar sözcükler:** Anastomoz, bronşiyal sleeve lobektomi, sleeve rezeksiyon.

techniques.<sup>[5]</sup> In line with the developments in surgical techniques, the first videothoracoscopic BSL case was published in 2002 and, currently, the minimally invasive BSL procedure has become widespread in advanced centers.<sup>[6]</sup> Eventually, with the application of robotic techniques in thoracic surgery, bronchial sleeve resections can be performed robotically in various centers around the world, and related series were published in the literature.<sup>[7]</sup> Although BSL can be applied to all lobar and some segmental bronchi, the most common application in practice is right upper BSL followed by left upper BSL.<sup>[1]</sup> Bronchial sleeve lobectomy is often indicated for malignancy in adult patients, whereas it is performed for benign strictures in the pediatric group.<sup>[8]</sup> In addition, it has been reported that BSL can be performed successfully in post-traumatic bronchial rupture, fistula and stenosis.<sup>[9]</sup>

**Corresponding author:** Muhammet Sayan.

E-mail: drsayann@gmail.com

Doi: 10.5606/tgkdc.dergisi.2023.24715

**Received:** February 02, 2023

**Accepted:** February 02, 2023

**Published online:** April 25, 2023

**Cite this article as:** Sayan M, Taştepe Aİ. Bronchial sleeve resections. Turk Gogus Kalp Dama 2023;31(Suppl 1):S21-S28. doi: 10.5606/tgkdc.dergisi.2023.24715.

©2023 All right reserved by the Turkish Society of Cardiovascular Surgery.



This is an open access article under the terms of the Creative Commons Attribution-NonCommercial License, which permits use, distribution and reproduction in any medium, provided the original work is properly cited and is not used for commercial purposes (<http://creativecommons.org/licenses/by-nc/4.0/>).

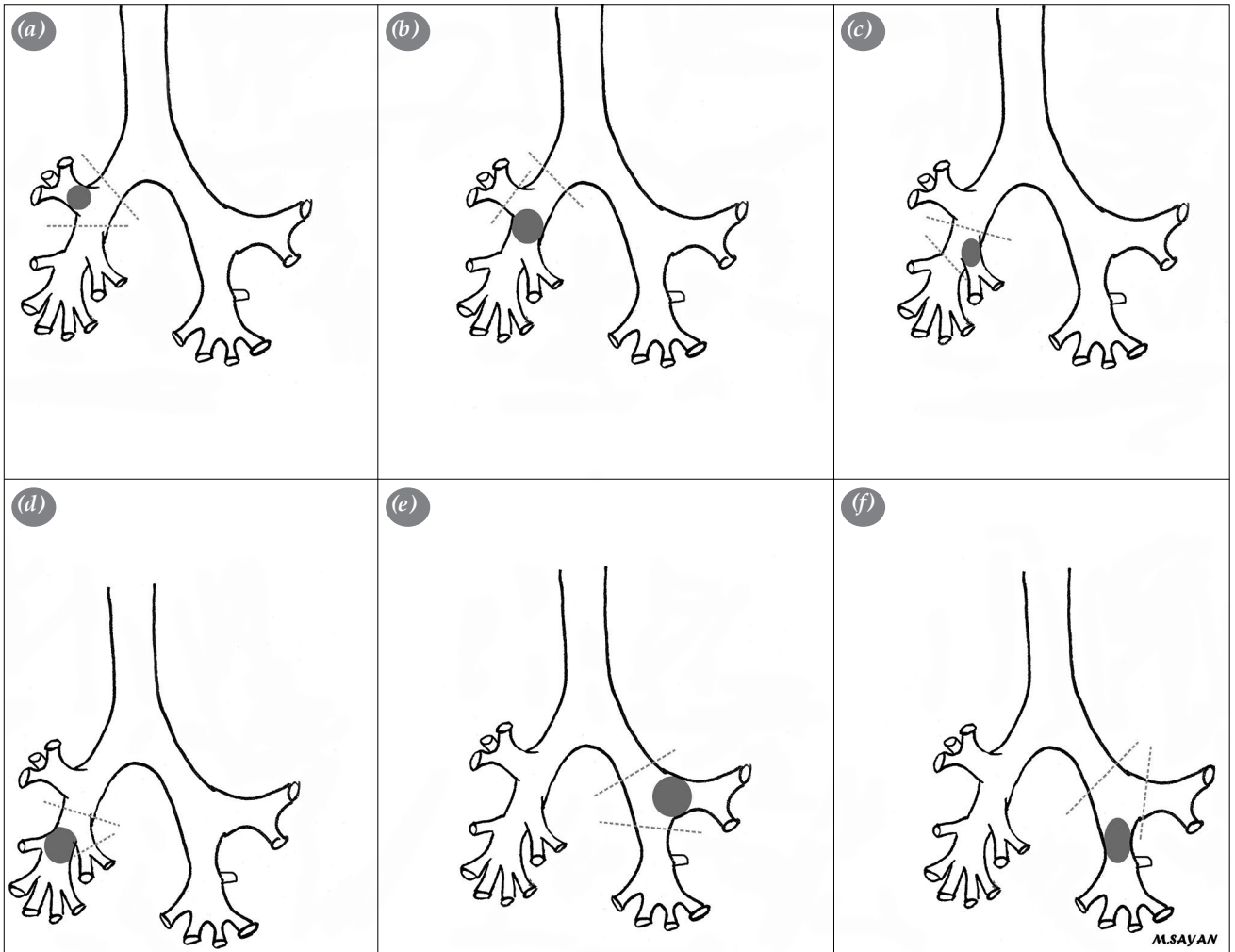
### Indications

Approximately 6 to 8% of lung cancer requires BSL due to endobronchial or peribronchial invasion. In addition, the presence of metastatic interlobar lymph nodes causing bronchial invasion may be an indication for sleeve resection. Patients with endobronchial carcinoid tumors and hamartomas may be candidates for sleeve resection. Other rare indications are bronchial strictures due to trauma or inflammatory diseases, and airway complications after lung transplantation.<sup>[1,2]</sup>

### Patient selection

Localization of the lesion is of utmost importance for the selection of patients who are candidate for BSL. Standard lobectomy may be risky in terms of oncological principles for some patients with a mass

with endobronchial extension or peribronchial invasion. These individuals should be evaluated for BSL to avoid pneumonectomy (Figure 1). Evaluations of patients should be started with a careful history taking and physical examination. Physicians should question about the patient's previous surgery, chemoradiotherapy status, nutritional status, medications (particularly immunosuppressive and anti-inflammatory drugs), presence of rheumatological disease, and comorbidities. Stair climbing and effort capacity should be noted, indicating pulmonary reserve of the patient. On physical examination, conditions that may cause inoperability such as supraclavicular, scalene lymphadenopathy, cachexia, and hoarseness should be investigated. Routine preoperative evaluations should be performed in those who are scheduled for cancer resection. Routine blood tests, electrocardiography, pulmonary



**Figure 1.** The illustration shows location of the lesions for various sleeve resection indications. (a) Right upper sleeve lobectomy. (b) Right sleeve bilobectomy inferior. (c) Right middle sleeve lobectomy. (d) Right lower sleeve lobectomy. (e) Left upper sleeve lobectomy. (f) Left lower sleeve lobectomy.

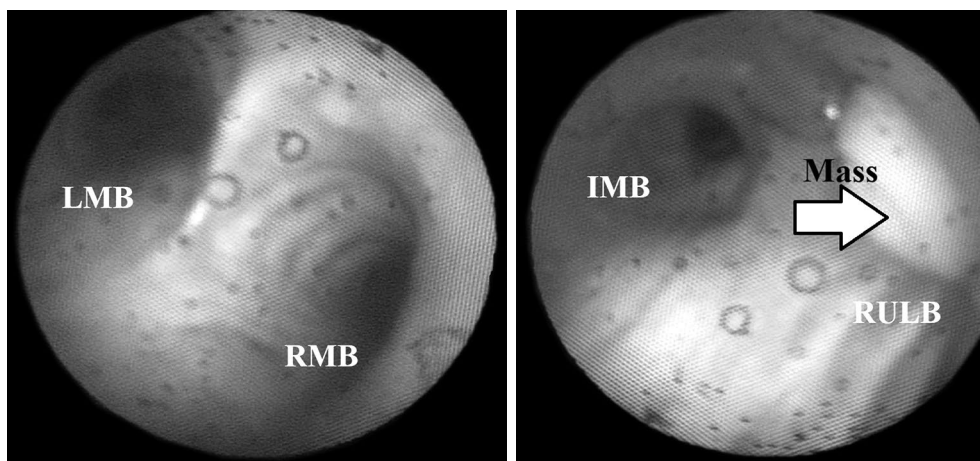
function test, carbon monoxide diffusion test, thoracic tomography, positron emission tomography (PET)-computed tomography (CT) and cranial magnetic resonance imaging (MRI), and non-invasive and invasive mediastinal lymph node evaluation should be performed. Thoracic CT should be contrast-enhanced in patients with normal renal function. Pulmonary artery invasion and the need for arterioplasty or arterial sleeve resection should not be ignored, particularly in patients with left-sided lesions who are candidates for BSL. The necessity of pneumonectomy should be considered in patients who are scheduled for BSL, and advanced evaluations such as ventilation/perfusion scintigraphy and cardiopulmonary stress test should be performed if necessary to evaluate the postoperative pulmonary status. Next, the surgeon should determine the presence and extent of the endobronchial lesion by fiberoptic bronchoscopy for whether the BSL procedure is sufficient and the necessity for further resection, such as extended sleeve lobectomy, pneumonectomy, and carina resection (Figure 2).

### Technique

The BSL procedure is performed under selective lung ventilation with a double-lumen tube in lateral decubitus position. In general, a right double-lumen tube should be preferred for left-side BSL and a left double-lumen tube for right-side BSL. Preferably, before intubation, fiberoptic or rigid bronchoscopy is performed to evaluate the current endobronchial status of mass. Although the common approach is thoracotomy, minimally invasive methods have been used successfully in recent years.<sup>[5,10]</sup> When a pedicled intercostal muscle flap is preferred, the flap should

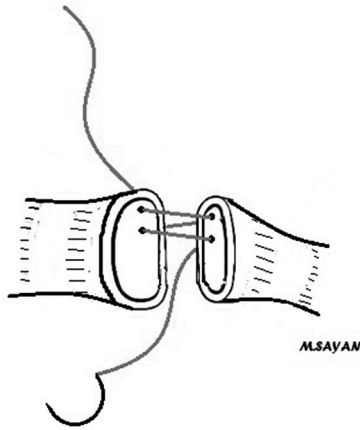
be prepared without placing an intercostal retractor to prevent muscle damage in patients undergoing thoracotomy.<sup>[11]</sup> The tumor resectability should be evaluated before irreversible surgical procedures such as vascular or bronchial division. Standard lobectomy procedures are performed consecutively, until the bronchial division. Mediastinal lymph node dissection, particularly subcarinal stations, should be completed prior to bronchial division to prevent any damage to the bronchial anastomosis. Peribronchial extensive dissection can cause bronchial ischemia and anastomotic complication and, thus, it is not recommended.<sup>[12,13]</sup> After the division of pulmonary vein and artery of the lobe to be resected, the proximal and distal bronchial parts are cut with a scalpel or scissors and, frozen-section is sent from both surgical margins. The surgeon must be certain of tumor-free margins before starting the bronchial anastomosis. To date, various techniques have been defined for bronchial anastomosis:

1. Running suture technique with monofilament absorbable or non-absorbable suture materials (polydioxanone or polypropylene);
2. Running suture technique with a monofilament suture (polydioxanone) on the contralateral side of the surgeon and lower part of anastomosis, interrupted technique with a multifilament absorbable suture (polyglactin) on surgeon's side and upper part;
3. Completely interrupted technique after lateral fixation sutures;
4. Telescopic technique for bronchial mismatch.



**Figure 2.** Flexible bronchoscopy imaging shows a tumor originating from the right upper lobe and extending into the right main bronchus.

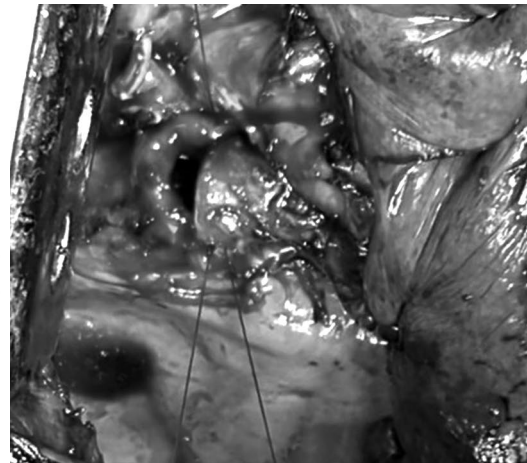
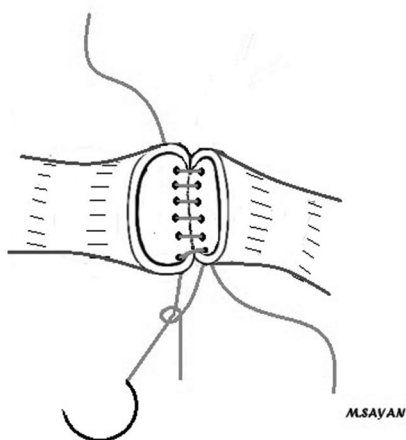
LMB: Left main bronchus; RMB: Right main bronchus; IMB: Intermediate bronchus; RULB: Right upper lobe bronchus.



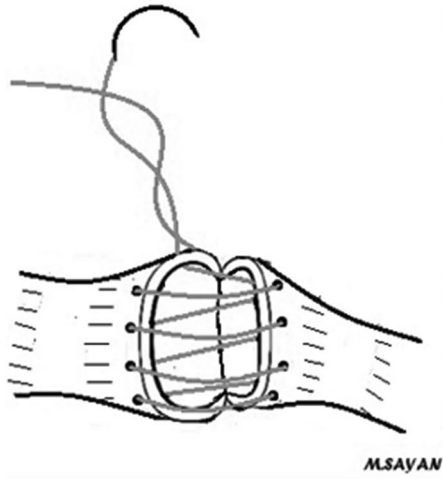
**Figure 3.** The anastomosis begins at the proximal bronchus with the first suture that is passed from the outside to the inside and continues from the distal end from the outside to the inside.

We prefer running suture technique in our department. Bronchial anastomosis is started from the opposite of the surgeon with a 4/0 or 3/0 polydioxanone suture material in accordance with the bronchial width and thickness. The first suture inserted in proximal bronchial end from the outside-to-inside, then, it is continued to the distal bronchus part from the inside to the outside (Figure 3). The surgeon completes the anastomosis of the membranous part of bronchus with the running suture technique toward himself/herself. Meanwhile, the assistant should hold tightly of the other end of the suture. In the anastomosis of the membranous side, the suture is passed from the inside to the outside with the final maneuver. The surgeon

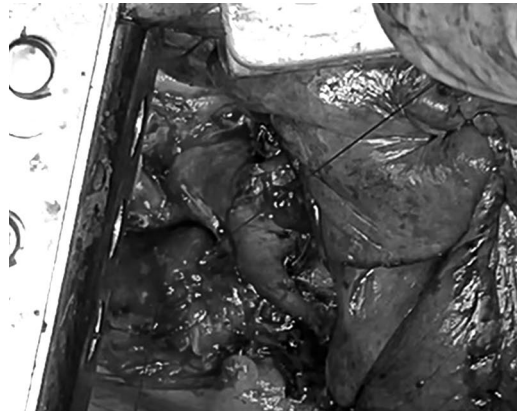
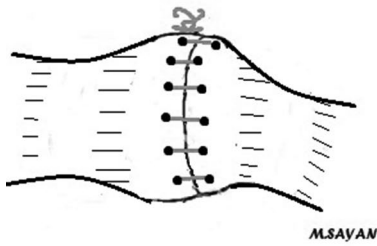
passes inside and outside again with a second suture material from his/her side and knots the ends of this suture and the first suture with the appropriate tension. The knots should be outside the bronchial lumen while tying the sutures (Figure 4). Before the knotting, surgeon should check for proper closure in the posterior part of the bronchus. If there is loosening, suture layers are pulled one by one with a hook or a thin right angle clamp tip to ensure optimal tension and closure. The surgeon continues the anastomosis with the running technique with the second suture material and the first suture tip is reached and the anastomosis is completed (Figure 5). Other techniques such as running suture for membranous part and



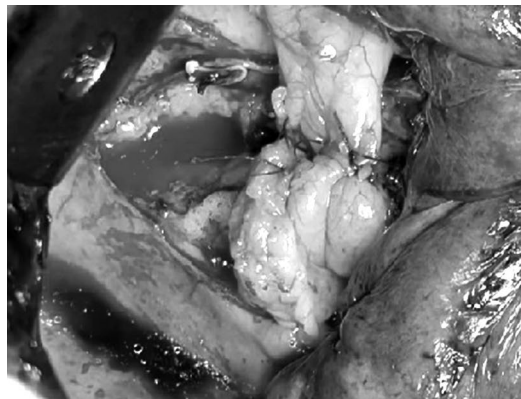
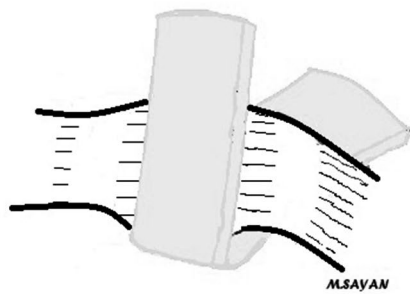
**Figure 4.** The inner side is sutured as described, and the end of the suture is held out posteriorly by passing it from the inside to the outside. A second suture (green color) is passed from the outside to the inside, then the inside to the outside, and all sutures are tied with the first suture tip at the extraluminal region of bronchus.



**Figure 5.** The outer face anastomosis is completed as running technique with the second suture material (green color).



**Figure 6.** Sutures are knotted extraluminally at the anterior region and anastomosis is completed.



**Figure 7.** The bronchial anastomosis should be buttressed by a pedicled tissue (e.g., pericardial adipose tissue, thymus, intercostal muscle, diaphragm).

interrupted sutures for cartilaginous part or fully interrupted technique may be preferred in various centers. The reason for preference may be to reduce the risk of complete bronchial dehiscence, in case of possible suture breaking due to infective reasons.<sup>[14-17]</sup> However, in an experimental study conducted by Bayram et al.,<sup>[18]</sup> there was no significant difference in the rate of bronchial dehiscence or complications in running or interrupted technique. If there is a diameter mismatch during anastomosis, passing the sutures from the large-diameter bronchus more widely than the narrow-diameter bronchus may provide a solution. Narrowing the membranous side of the wide bronchus with an additional suture is another option. Wedge resection on the cartilage side of the large diameter bronchus is not preferred, as it increases the risk of fistula. Although it is not preferred in our clinic, another solution to bronchial diameter mismatch is telescopic anastomosis.<sup>[2,17,19,20]</sup> Effective closure of the bronchial ends is observed, and anterior sutures are also tied and anastomotic leakage is tested with 25 to 30 cm H<sub>2</sub>O air pressure (Figure 6). Minor air leaks at the insertion site of the suture needle should not be considered. Supporting with polyglactin sutures can be applied to areas with significant leakage. According to the surgeon's preference, the bronchial buttressing should be performed with a tissue such as intercostal pedicle flap, pleura, pericardial adipose tissue, thymus or diaphragm, and omental tissue, particularly in patients with a high risk of anastomosis complications due to comorbidity (Figure 7).<sup>[12,21]</sup>

### Postoperative period

Patients should be transferred to the intensive care unit as extubated as much as possible. Postoperative follow-up of patients with sleeve resection is not much different from standard lung resection. Before extubating, a bronchoscopy should be performed to check for secretion clearance, anastomosis control, and the presence of bronchial stenosis. During follow-up, drainage monitoring, cardiac rhythm monitoring, urine output, respiratory physiotherapy, complete blood count and electrolyte monitoring are performed. A chest X-ray provides important information about the expansion of the remaining lung and possible complications. Intravenous fluid support is provided by paying attention to pulmonary edema.<sup>[12]</sup>

## RESULTS

Studies comparing sleeve lobectomy and pneumonectomy for lung cancer emphasized the superiority of sleeve lobectomy in terms of morbidity and early mortality. Shi et al.<sup>[22]</sup> reported that, in

a meta-analysis, sleeve lobectomy was superior in terms of morbidity and mortality, as well as long-term survival. Li et al.<sup>[23]</sup> also showed that the risk of tumor recurrence was not increased in BSL compared to pneumonectomy. In another study, even sleeve lobectomy after induction chemotherapy was found to be superior to pneumonectomy in terms of morbidity and long-term survival.<sup>[24]</sup> Similarly, in a propensity score analysis by Chen et al.,<sup>[25]</sup> the superiority of sleeve lobectomy was emphasized in terms of short- and long-term survival. Lee et al.<sup>[26]</sup> reported that pneumonectomy was superior to BSL in terms of three-year overall survival and disease-free survival, although the difference was not statistically significant.

### Complications

The most common complications are atelectasis, pneumonia, and bronchial dehiscence. These complications are associated with the secretion and blood accumulation in the anastomosis line or impaired mucociliary activity due to mucosal damage.<sup>[2]</sup> Such complications can be prevented by some measures such as early mobilization and respiratory physiotherapy and suitable antibiotic therapy. During follow-up, sudden onset of subcutaneous emphysema, unresolved atelectasis, lobar consolidation, hemoptysis, and prolonged air leakage more than one week postoperatively are the indicators of bronchial dehiscence and these patients should undergo bronchoscopy. During bronchoscopy, the necrotic bronchial part is seen in gray-white color. Large areas of dehiscence can be visualized directly by bronchoscopy. Risk factors for complication are low forced expiratory volume in 1 sec (FEV1), increased pulmonary artery pressure, active smoking, induction chemo-radiotherapy, diabetes mellitus, malnutrition, coronary artery disease, and right-sided resections.<sup>[27]</sup> Bronchoarterial fistula is a very rare and mortal complication. Although the use of non-absorbable suture materials such as polypropylene, lack of support tissue between the pulmonary artery and bronchus, and the aforementioned risk factors for bronchial fistula are blamed for the fistula occurring, the exact etiology is not clear. Peribronchial buttressing not only prevents air leaks, but also provides protection against possible arterial fistula.<sup>[28,29]</sup> Tumor recurrence in the late period is an undesirable aspect of sleeve resections. Bronchial stenosis, another late complication, has been reported at a rate of 2 to 6% after bronchoplastic resections. Segmentary ischemia and formed granulation tissue have been accused in the etiology. Surgical methods such as re-anastomosis, complementary pneumonectomy, and non-surgical methods such as bronchoscopy, laser, and stent are used in the treatment of patients.<sup>[30]</sup>

Sleeve resection procedure was performed in a total of 115 patients with non-small cell lung cancer between 2010 and 2022 at Gazi University, Faculty of Medicine, Department of Thoracic Surgery, and during the study period, 1,528 patients underwent anatomic resection for lung cancer with a rate of 7.5%. The mean age was 61.7±10.8 years and the median tumor diameter was 3.5 cm. Sixteen (13.9%) patients were female. The most common surgical procedure was right upper BSL in 62 (53.9%) patients, followed by left upper BSL in 27 (23.5%) patients. Predominant histopathology, as expected, was a squamous cell carcinoma in 73 (63.5%) patients. Lymph node metastasis was detected at N2 stations in 16 (13.9%) patients in the pathological staging. In our series, the number of patients with R1 resection was five (4.3%). Anastomotic complications occurred in six (5.2%) patients and two of them (1.7%) died from bronchovascular fistula within 30 days postoperatively. Other anastomotic complications were bronchial dehiscence, and the approach was completion pneumonectomy in three (2.6%) patients and re-anastomosis in one (0.8%) patients.

In conclusion, bronchial sleeve resections can be performed successfully not only in patients with limited respiratory reserve, but also in patients with adequate respiratory function, without compromising oncological principles. Careful patient selection, appropriate intraoperative manipulations, and effective postoperative care are required to prevent anastomotic complications. Postoperative hemoptysis, a fatal complication, should be a warning for bronchoarterial fistulas.

**Author Contributions:** All authors contributed equally to the article.

**Conflict of Interest:** The authors declared no conflicts of interest with respect to the authorship and/or publication of this article.

**Funding:** The authors received no financial support for the research and/or authorship of this article.

## REFERENCES

1. Yu JA, Weyant MJ. Techniques of bronchial sleeve resection. *Semin Cardiothorac Vasc Anesth* 2012;16:196-202. doi: 10.1177/1089253212452153.
2. De Leyn P, Decaluwe H. Sleeve lobectomy. In: Locicero J, Feins RH, Colson YL, Rocco G, editors. *Shield's General Thoracic Surgery*. 8th ed. Wolters Kluwer; 2018. p. 832-59.
3. Sayan M, Bas A, Gokce A, Dikmen AU, Celik A, Kurul IC, et al. Surgical outcomes of sleeve resections performed for non-small cell lung cancer; A single center experience. *Niger J Clin Pract* 2020;23:829-34. doi: 10.4103/njcp.njcp\_603\_18.
4. Thomas CP. Conservative resection of the bronchial tree. *J R Coll Surg Edinb* 1956;1:169-86.
5. Zhu XY, Ding C, Xu C, Chen J, Ju S, Pan S, et al. Techniques and outcomes of bronchoplastic and sleeve resection: An 8-year single-center experience. *Transl Lung Cancer Res* 2021;10:4538-48. doi: 10.21037/tlcr-21-913.
6. Celik A, Sayan M. Videothoroscopic bronchial sleeve resection for non-small cell lung cancer. *Cureus* 2021;13:e13686. doi: 10.7759/cureus.13686.
7. Jin D, Dai Q, Han S, Wang K, Bai Q, Gou Y. Comparison of effect between Da Vinci robot-assisted and traditional thoroscopic bronchial sleeve lobectomy. *Asian J Surg* 2022;S1015-9584(22)01589-5. doi: 10.1016/j.asjsur.2022.11.029.
8. Gaissert HA, Mathisen DJ, Grillo HC, Vacanti JP, Wain JC. Tracheobronchial sleeve resection in children and adolescents. *J Pediatr Surg* 1994;29:192-7. doi: 10.1016/0022-3468(94)90316-6.
9. Porhanov VA, Poliakov IS, Selvaschuk AP, Grechishkin AI, Sitnik SD, Nikolaev IF, et al. Indications and results of sleeve carinal resection. *Eur J Cardiothorac Surg* 2002;22:685-94. doi: 10.1016/s1010-7940(02)00523-7.
10. Liu A, Zhao Y, Qiu T, Xuan Y, Qin Y, Sun X, et al. The long-term oncologic outcomes of robot-assisted bronchial single sleeve lobectomy for 104 consecutive patients with centrally located non-small cell lung cancer. *Transl Lung Cancer Res* 2022;11:869-79. doi: 10.21037/tlcr-22-298.
11. Rendina EA, Venuta F, Ricci P, Fadda GF, Bognolo DA, Ricci C, et al. Protection and revascularization of bronchial anastomoses by the intercostal pedicle flap. *J Thorac Cardiovasc Surg* 1994;107:1251-4.
12. Bölükbas S, Baldes N, Bergmann T, Eberlein M, Beqiri S. Standard and extended sleeve resections of the tracheobronchial tree. *J Thorac Dis* 2020;12:6163-72. doi: 10.21037/jtd.2020.02.65.
13. Yamamoto K, Miyamoto Y, Ohsumi A, Kojima F, Imanishi N, Matsuoka K, et al. Sleeve lung resection for lung cancer: Analysis according to the type of procedure. *J Thorac Cardiovasc Surg* 2008;136:1349-56. doi: 10.1016/j.jtcvs.2008.05.018.
14. Weisel RD, Cooper JD, Delarue NC, Theman TE, Todd TR, Pearson FG. Sleeve lobectomy for carcinoma of the lung. *J Thorac Cardiovasc Surg* 1979;78:839-49.
15. Kutlu CA, Goldstraw P. Tracheobronchial sleeve resection with the use of a continuous anastomosis: Results of one hundred consecutive cases. *J Thorac Cardiovasc Surg* 1999;117:1112-7. doi: 10.1016/s0022-5223(99)70247-3.
16. Hamad AM, Marulli G, Rizzardi G, Schiavon M, Zuin A, Breda C, et al. Multiple-running suture technique for bronchial anastomosis in difficult sleeve resection. *Ann Thorac Surg* 2009;87:975-6. doi: 10.1016/j.athoracsur.2008.07.029.
17. Hollaus PH, Janakiev D, Pridun NS. Telescope anastomosis in bronchial sleeve resections with high-caliber mismatch. *Ann Thorac Surg* 2001;72:357-61. doi: 10.1016/s0003-4975(01)02780-1.
18. Bayram AS, Erol MM, Salci H, Ozyiğit O, Görgül S, Gebitekin C. Basic interrupted versus continuous suturing techniques in bronchial anastomosis following sleeve

- lobectomy in dogs. *Eur J Cardiothorac Surg* 2007;32:852-4. doi: 10.1016/j.ejcts.2007.09.005.
19. Toyooka S, Soh J, Oto T, Miyoshi S. Bronchoplasty to adjust mismatches in the proximal and distal bronchial stumps during bronchial sleeve resection of the left lower lobe and lingular division. *Eur J Cardiothorac Surg* 2013;43:182-3. doi: 10.1093/ejcts/ezs379.
  20. Galetta D, Spaggiari L. Right side sleeves. *Shanghai Chest* 2017;1:33. doi: 10.21037/shc.2017.09.01.
  21. Ceylan KC, Batuhan G, Kaya ŞÖ. Novel method for bronchial stump coverage for prevents postpneumonectomy bronchopleural fistula: Pedicled thymopericardial fat flap. *J Cardiothorac Surg* 2022;17:286. doi: 10.1186/s13019-022-02032-0.
  22. Shi W, Zhang W, Sun H, Shao Y. Sleeve lobectomy versus pneumonectomy for non-small cell lung cancer: A meta-analysis. *World J Surg Oncol* 2012;10:265. doi: 10.1186/1477-7819-10-265.
  23. Li Z, Chen W, Xia M, Liu H, Liu Y, Inci I, et al. Sleeve lobectomy compared with pneumonectomy for operable centrally located non-small cell lung cancer: A meta-analysis. *Transl Lung Cancer Res* 2019;8:775-86. doi: 10.21037/tlcr.2019.10.11.
  24. Maurizi G, D'Andrilli A, Anile M, Ciccone AM, Ibrahim M, Venuta F, et al. Sleeve lobectomy compared with pneumonectomy after induction therapy for non-small-cell lung cancer. *J Thorac Oncol* 2013;8:637-43. doi: 10.1097/JTO.0b013e318286d145.
  25. Chen J, Soultanis KM, Sun F, Gonzalez-Rivas D, Duan L, Wu L, et al. Outcomes of sleeve lobectomy versus pneumonectomy: A propensity score-matched study. *J Thorac Cardiovasc Surg* 2021;162:1619-28.e4. doi: 10.1016/j.jtcvs.2020.08.027.
  26. Lee HK, Lee HS, Kim KI, Shin HS, Lee JW, Kim HS, et al. Outcomes of sleeve lobectomy versus pneumonectomy for lung cancer. *Korean J Thorac Cardiovasc Surg* 2011;44:413-7. doi: 10.5090/kjtcs.2011.44.6.413.
  27. Yildizeli B, Fadel E, Mussot S, Fabre D, Chataigner O, Darteville PG. Morbidity, mortality, and long-term survival after sleeve lobectomy for non-small cell lung cancer. *Eur J Cardiothorac Surg* 2007;31:95-102. doi: 10.1016/j.ejcts.2006.10.031.
  28. Marjanski T, Sternau A, Dziedzic R. Arteriobronchial fistula complicating right upper lobectomy. *Ann Thorac Surg* 2013;96:e95-6. doi: 10.1016/j.athoracsur.2013.03.109.
  29. Abe J, Hasumi T, Takahashi S, Tanaka R, Sato T, Okazaki T. Fatal broncho-pulmonary artery fistula after lobectomy for lung cancer. *J Surg Case Rep* 2015;2015:rjv110. doi: 10.1093/jscr/rjv110.
  30. Wallwork K, Belcher E. Post-lobectomy airways complications. *Shanghai Chest* 2021;5:18. doi: 10.21037/shc.2020.03.09.