

The impact of large proximal aortic neck on endovascular aneurysm repair outcomes

Geniş proksimal aort boyununun endovasküler anevrizma tamiri sonuçlarına etkisi

Bahadır Aytakin¹, Gökay Deniz¹, Ferit Çetinkaya², Serkan Mola¹, Naim Boran Tümer¹,
Ertekin Utku Ünal³, Ahmet Barış Durukan⁴, Hakki Zafer İşcan¹

Institution where the research was done:

Ankara City Hospital, Ankara, Türkiye

Author Affiliations:

¹Department of Cardiovascular Surgery, Ankara City Hospital, Ankara, Türkiye

²Department of Cardiovascular Surgery, Ağrı Training and Research Hospital, Ağrı, Türkiye

³Department of Cardiovascular Surgery, Ufuk University Medical Faculty, Ankara, Türkiye

⁴Department of Cardiovascular Surgery, Istinie University Medical Faculty, Istanbul, Türkiye

ABSTRACT

Background: This study aims to investigate the effect of large proximal aortic neck diameter on post-endovascular aneurysm repair clinical outcomes.

Methods: A total of 180 patients (168 males, 12 females; mean age: 69.9±7.4 years; range, 46 to 88 years) who underwent elective endovascular aneurysm repair between June 2016 and September 2021 were retrospectively analyzed. According to the proximal infrarenal aortic neck diameter, the patients were divided into two groups: Group 1 (<25 mm; normal aortic neck) and Group 2 (≥25 mm; pre-aneurysmatic aortic neck). Patient characteristics, proximal infrarenal aortic neck diameter measurements with computed tomography angiography, and clinical outcomes were recorded. The primary endpoint was to assess post-endovascular aneurysm repair aortic neck dilatation, mortality, endoleaks, overall survival, type 1a endoleaks-free survival, and event-free survival regarding the groups.

Results: There was no statistically significant difference in early mortality (p=0.55) and type 1a endoleak incidence between the groups (p=0.55). In Group 1, the mean change in diameter A (proximal infrarenal level) was 2.89±1.74 mm (p=0.01), and it was 2.31±2.1 mm in diameter B (proximal pre-aneurysm-sac level) (p=0.01). The mean change in Group 2 was 2.8±3.4 mm for diameter A (p<0.01) and 2.22±2.3 mm for diameter B (p<0.01). Aortic neck dilatation rates were similar between the groups (p=0.82 for diameter A; p=0.78 for diameter B). The five-year survival, event-free survival, and type 1a endoleak-free survival were also similar (p=0.54, p=0.26, p=0.24, respectively).

Conclusion: Our study results showed that patients with <25 mm and ≥25-mm aortic neck diameters had similar mid-term results and aortic neck dilatation ratio. Endovascular aneurysm repair outcomes can be improved with careful patient and graft selection, and early intervention for complications.

Keywords: Abdominal aortic aneurysm, endoleak, endovascular aneurysm repair.

ÖZ

Amaç: Bu çalışmada geniş proksimal aort boyun çapının endovasküler aort tamiri sonrası klinik sonuçlar üzerine etkisi incelendi.

Çalışma planı: Çalışmaya Haziran 2016 - Eylül 2021 tarihleri arasında elektif endovasküler anevrizma tamiri uygulanan toplam 180 hasta (168 erkek, 12 kadın; ort. yaş: 69.9±7.4 yıl; dağılım, 46-88 yıl) dahil edildi. Proksimal infrarenal aort boyun çapına göre hastalar iki gruba ayrıldı: Grup 1 (<25 mm; normal aort boynu) ve Grup 2 (≥25 mm; preanevrizmatik aort boynu). Hasta özellikleri, bilgisayarlı tomografi anjiyografi ile proksimal infrarenal aort boyun çapı ölçümleri ve klinik sonuçlar kaydedildi. Primer sonlanım noktası, gruplara göre endovasküler anevrizma tamiri sonrası aort boyun dilatasyonu, mortalite, endoleak, genel sağkalım, tip 1a endoleak olmaksızın sağkalım ve olaysız sağkalımı değerlendirmektir.

Bulgular: Erken mortalite (p=0.55) ve tip 1a endoleak insidansı (p=0.55) açısından gruplar arasında istatistiksel olarak anlamlı bir fark yoktu. Grup 1'de çap A'daki (proksimal infrarenal seviye) ortalama değişiklik 2.89±1.74 mm ve çap B'deki (anevrizma öncesi proksimal kese seviyesi) ortalama değişiklik 2.31±2.1 mm idi (p=0.01). Grup 2'deki ortalama değişiklik çap A için 2.8±3.4 mm (p<0.01) ve çap B için 2.22±2.3 mm idi (p<0.01). Gruplar arasında aort boyun dilatasyon oranları benzerdi (çap A için p=0.82; çap B için p=0.78). Beş yıllık sağkalım, olaysız sağkalım ve tip 1a endoleak olmaksızın sağkalım da benzerdi (sırasıyla, p=0.54, p=0.26, p=0.24).

Sonuç: Çalışma sonuçlarımız aort boyun çapı <25 mm ve ≥25 mm olan hastalarda orta dönem sonuçların ve aort boyun dilatasyon oranının benzer olduğunu gösterdi. Endovasküler anevrizma tamiri sonuçları dikkatli hasta ve greft seçimi ve komplikasyonlara erken müdahale ile iyileştirilebilir.

Anahtar sözcükler: Abdominal aort anevrizması, endoleak, endovasküler anevrizma tamiri.

Corresponding author: Bahadır Aytakin.

E-mail: bahadiraytekin@hotmail.com

Doi: 10.5606/tgkdc.dergisi.2023.25255

Received: June 13, 2023

Accepted: September 24, 2023

Published online: October 19, 2023

Cite this article as: Aytakin B, Deniz G, Çetinkaya F, Mola S, Tümer NB, Ünal EU, et al. The impact of large proximal aortic neck on endovascular aneurysm repair outcomes. Turk Gogus Kalp Dama 2023;31(4):489-497. doi: 10.5606/tgkdc.dergisi.2023.25255.

©2023 All right reserved by the Turkish Society of Cardiovascular Surgery.



This is an open access article under the terms of the Creative Commons Attribution-NonCommercial License, which permits use, distribution and reproduction in any medium, provided the original work is properly cited and is not used for commercial purposes (<http://creativecommons.org/licenses/by-nc/4.0/>).

After the endovascular revolution, priorities for aortic aneurysm treatment have evolved. Infrarenal endovascular aortic aneurysm repair (EVAR), which offers short-term advantages over open aortic surgery, has gained popularity worldwide. It is a less invasive technique with lower early morbidity and mortality besides the advantages of shorter hospital stays, more rapid rehabilitation, and more remarkable early overall survival.^[1,2]

The EVAR procedures mandate adequate sealing zones for successful early and late outcomes. Therefore, the infrarenal aortic neck morphology of an aneurysm is the key point in this respect.^[3] Excessive angulation of the neck, short neck length, circumferential thrombus, and reverse tapering may lead to poor proximal sealing zones causing endoleak and graft migration. However, sealing zone dilatation due to progressive aneurysmal degeneration may lead to stent graft failure, aneurysm sac dilatation, and subsequent morbidity in endovascular procedures. The proximal aortic neck dilatation has previously been investigated and shown in up to 24.6% of patients using larger diameter main body devices or excessive oversize, and the larger proximal aortic neck has been blamed in the literature for a

higher risk of type 1a endoleak and worse clinical outcomes.^[4,5]

In the present study, we aimed to investigate the aortic disease progression and post-EVAR anatomic changes due to endograft affecting aortic neck diameter and to evaluate the clinical outcomes after EVAR in the mid-term period.

PATIENTS AND METHODS

This single-center, retrospective, case-control study was conducted at Ankara City Hospital, Department of Cardiovascular Surgery between June 2016 and September 2021. The patients who underwent elective EVAR for infrarenal abdominal aortic aneurysms (AAAs) were screened. Those with emergency and ruptured AAAs were excluded. Finally, a total of 180 patients (168 males, 12 females; mean age: 69.9 ± 7.4 years; range, 46 to 88 years) who underwent elective EVAR, had at least one year of postoperative follow-up, and who had pre- and postoperative documented computed tomographic angiography (CTA) scans were included.

As CTA measurements, diameter A was defined as the diameter of the aneurysm neck at the infrarenal

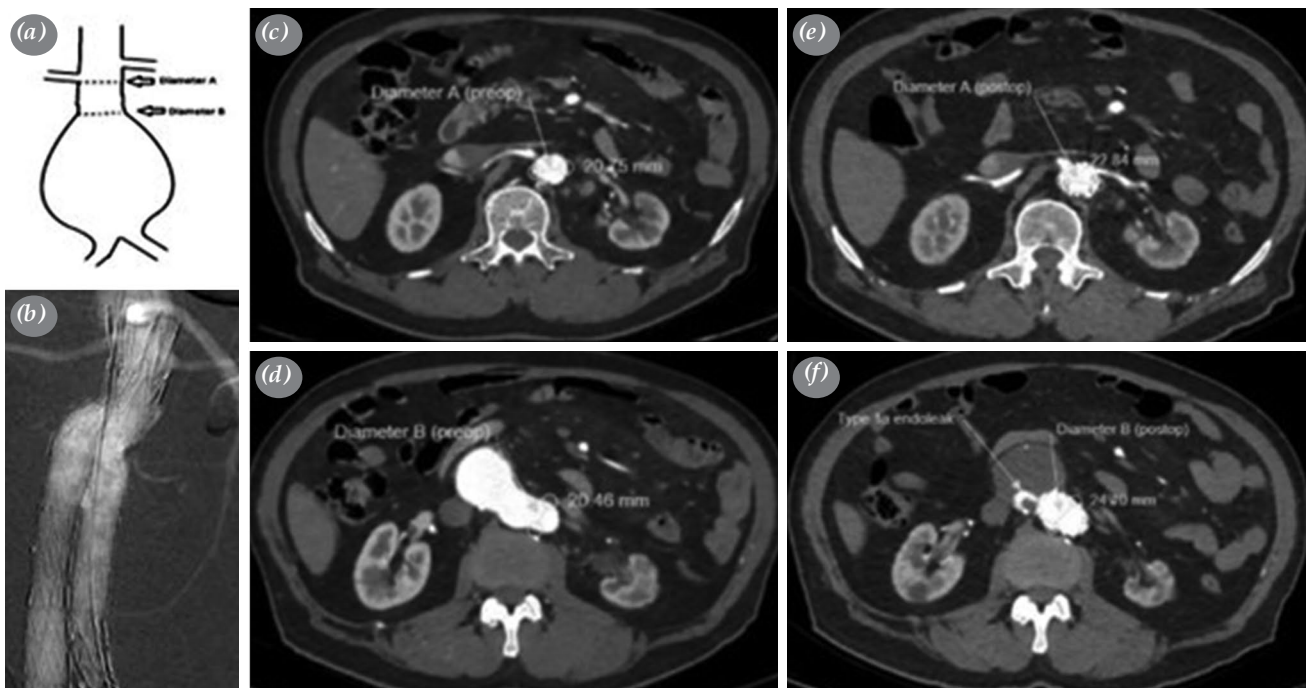


Figure 1. (a) Preoperative measurements with assessing the CT angiography images. (b) %20 oversizing with 24 mm EVAR graft. (c) Preoperative measurements of Diameter A; (d) Preoperative measurements of Diameter B; (e) Postoperative measurements of Diameter A. (f) The enlargement of Diameter B after postoperative 6th month CT control and detected type 1a endoleak.

EVAR: Endovascular aortic repair; CT: Computed tomography.

level, and diameter B was defined as the pre-sac diameter of the aneurysm neck (Figure 1). According to the proximal infrarenal aortic neck diameter (PIAND), the patients were divided into two groups: Group 1 (n=113) consisted of patients having normal (<25 mm) diameter A on CTA and Group 2 (n=67) consisted of patients with aneurysmatic (≥25 mm) proximal aortic neck diameter A on CTA. As a cut-off value, 25-mm PIAND was previously described as suitable for defining the border of the pre-aneurysmal neck diameter and it is currently used as a cut-off for defining large aortic neck diameter in the AAA screening programs.^{16,71} Thus, we divided the patients into two groups according to this cut-off value and compared the results of patients with a normal aortic neck diameter to those with an abnormal pre-aneurysmal diameter to understand aortic disease progression.

All patients were operated by a single endovascular team in the hybrid operating room under general, local or regional anesthesia. For every patient, a standard EVAR procedure was initiated with heparin administration (5,000 IU intravenous bolus) and femoral access. Modular endografts (Medtronic Endurant™ II, Medtronic Inc., Minneapolis, MN, USA and Lifetech Ankura™ TAA Stent Graft, Lifetech Scientific, Shenzhen, China) were used in 174 patients and unibody

endografts (Endologix AFX®, Endologix Inc., Irvine, CA, USA - Bifurcated Endograft System) were used in six patients. In all operations, 15 to 20% oversizing was applied according to the widest neck diameter (diameter A or diameter B). A completion angiogram was performed to document the status after endograft implantation. Smoking reduction, beta-blocker, antiplatelet and statin therapy were administrated in postoperative follow-up for all. During follow-up, control CTA was performed postoperatively, and the diameter exchanging, measurements were documented. Demographic data of the patients and perioperative data were obtained from the hospital database. Both groups were compared in terms of age, sex (male), diabetes mellitus, hypertension, hyperlipidemia, chronic obstructive pulmonary diseases, chronic kidney diseases, peripheral vascular diseases, coronary artery bypass graft, chronic heart failure, cerebrovascular event, cancer, smoking and history of abdominal surgery.

The primary endpoint was to investigate the changes in neck morphology after EVAR within the groups. The relationship between mid-term type 1a endoleak development and survival analysis with proximal aortic neck diameter was investigated as a secondary endpoint. Pre- and postoperative diameter A and diameter B values were measured within the groups,

Table 1. Baseline characteristics of patients undergoing EVAR

Demographic features	Group 1 (n=113)			Group 2 (n=67)			p
	n	%	Mean±SD	n	%	Mean±SD	
Age (year)			70±7.7			69.7±7	0.80
Sex							
Male	103	91.2		65	97.0		0.12
Diabetes mellitus	31	27.4		13	19.4		0.22
Hypertension	83	73.5		47	70.1		0.63
Hyperlipidemia	32	28.3		23	34.3		0.39
Chronic obstructive pulmonary diseases	26	23.0		18	26.9		0.56
Renal failure	10	8.8		8	11.9		0.50
Peripheral vascular diseases	10	8.8		2	3.0		0.12
Coronary artery bypass graft	19	16.8		10	14.9		0.73
Chronic heart failure	4	3.5		1	1.5		0.65
Cerebrovascular event	6	5.3		5	7.5		0.56
Cancer	3	2.7		0	0.0		0.29
Smoker	57	50.4		39	58.2		0.31
History of abdominal surgery	4	3.5		2	3.0		0.90

EVAR: Endovascular aortic repair; SD: Standard deviation.

Table 2. Perioperative measurements following the EVAR procedures

	Group 1 (n=113)				Group 2 (n=67)				p		
	n	%	Mean±SD	Min-Max	95% CI	n	%	Mean±SD		Min-Max	95% CI
Clinical outcomes											
Endoleaks	19	16.8				14	20.9				0.55
Type 1a endoleaks	3	2.7				4	5.9				0.71
Mortality	19	16.8				14	20.9				0.55
Proximal neck diameters											
Preoperative diameter A (mm)			21.5±2	16-24				26.7±2.2	25-34		0.001
Postoperative diameter A (mm)			24.5±2.4	20-30				29.6±4.5	25-36		0.001
The enlargement of diameter A (mm)			2.89±1.74		2.5-3.2			2.8±3.4	1.9-3.6		0.82
p value			<0.01					<0.01			
Preoperative diameter B (mm)			22.5±2.8	15-28				27.5±2.9	20-38		0.001
Postoperative diameter B (mm)			24.8±2.5	18-32				29.3±2.7	23-38		0.001
The enlargement of diameter B (mm)			2.31±2.1		1.9-2.7			2.22±2.3	1.6-2.7		0.78
p value			<0.01					<0.01			
Follow-up time (day)			1451±549					1376±499			0.249

EVAR: Endovascular aortic repair; CI: Confidence interval; SD: Standard deviation.

and statistically significant differences within and between the groups were investigated. The survival curves of the two groups were compared. The groups were examined for type 1 endoleak occurrence over the years, since aneurysm neck growth is known to be linked to it. All type 1 endoleaks were intervened. Finally, type 1 endoleak occurrence, all mortalities were admitted as an event, and the groups were compared to event-free survival curves.

Statistical analysis

Statistical analysis was performed using the SPSS version 20.0 software (IBM Corp., Armonk, NY, USA). Descriptive data were expressed in mean ± standard deviation (SD), median (min-max) or number and frequency, where applicable. The difference between the groups in terms of comorbid factors was analyzed using the chi-square and Fisher exact chi-square test. Differences in mortality and type 1a endoleak development were evaluated by chi-square and Fisher exact chi-square test. Diameter changes and the differences between the two groups were investigated with paired simple t-tests and independent sample t-test. Overall survival, type 1a endoleak-free survival, and event-free survival estimation of six years were analyzed with the log-rank analysis of the Kaplan-Meier method. A p value of <0.05 was considered statistically significant with 95% confidence interval (CI).

RESULTS

There was no significant difference between the groups in terms of age (p=0.80), sex (p=0.12), and comorbidities (Table 1).

The mean follow-up was 29.4±11.7 months. A total of 33 (18.3%) endoleaks were observed, 19 (16.8%) of which were in Group 1 and 14 (20.8%) of which were in Group 2. There was no significant difference between the groups regarding endoleak occurrence (p=0.55). Type 1a endoleak was seen in three patients (2.6%) in Group 1 and four (5.9%) in Group 2, and it was seen in seven (3.8%) patients in total. There was no significant difference between the groups regarding type 1a endoleak (p=0.42). All type 1a endoleaks were treated with aortic cuff extension and ballooning. No device migration was observed in any patient. A total of 33 deaths were reported, with an overall mortality rate of 18.3%. Nineteen (16.8%) of them were in Group 1, while 14 (20.8%) of them were in Group 2. In terms of mortality, there was no significant difference between the groups (p=0.55).

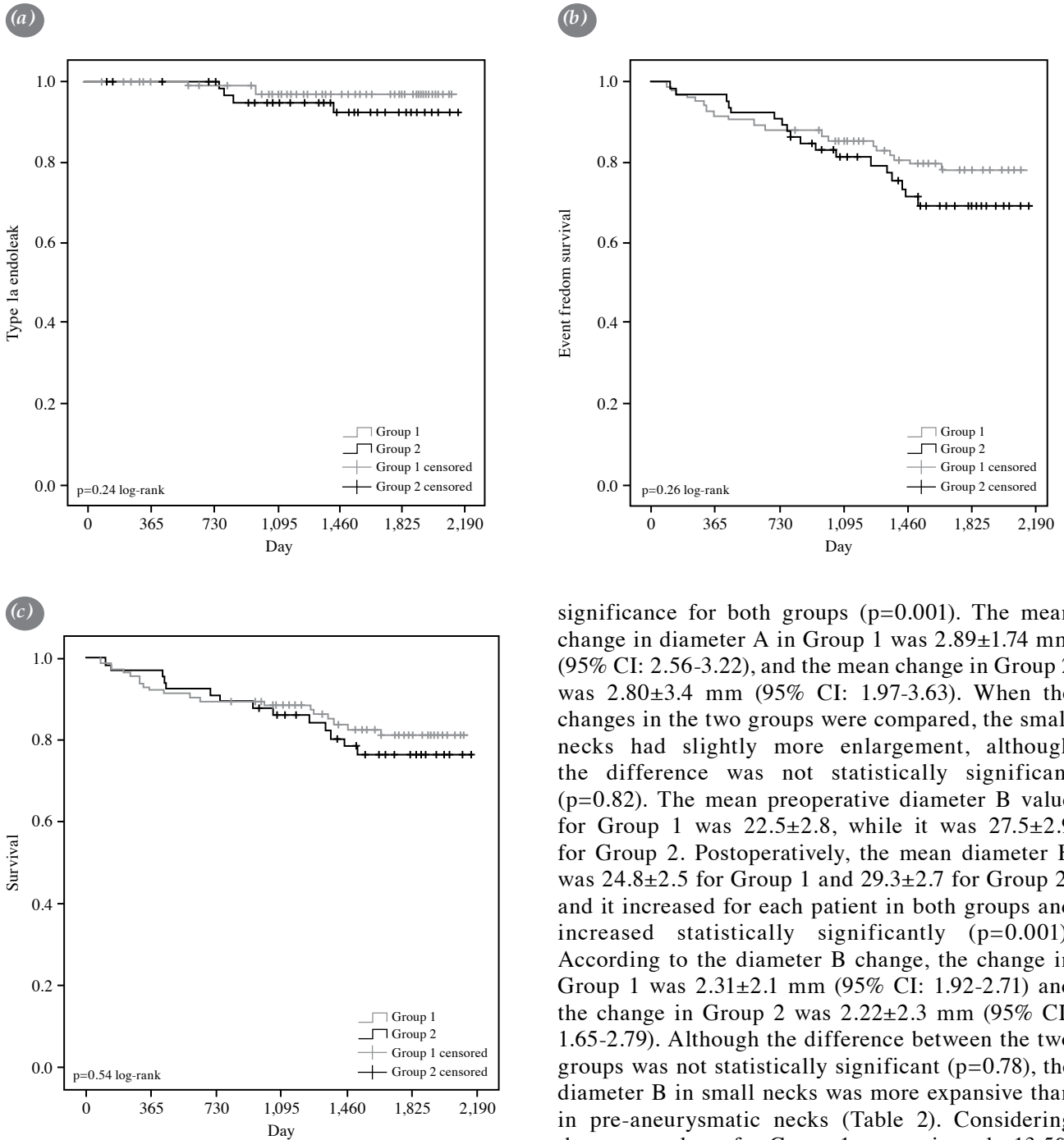


Figure 2. (a) Cumulative Kaplan-Meier estimate for type Ia endoleaks-free survival, (b) event-free survival, and (c) overall survival in years.

A mean preoperative diameter A value of 21.5 ± 2 mm was obtained for Group 1 and 26.7 ± 2.2 mm was obtained for Group 2. Postoperatively, the mean diameter A was 24.5 ± 2.4 mm for Group 1 and 29.6 ± 4.5 mm for Group 2; indicating statistically

significance for both groups ($p=0.001$). The mean change in diameter A in Group 1 was 2.89 ± 1.74 mm (95% CI: 2.56-3.22), and the mean change in Group 2 was 2.80 ± 3.4 mm (95% CI: 1.97-3.63). When the changes in the two groups were compared, the small necks had slightly more enlargement, although the difference was not statistically significant ($p=0.82$). The mean preoperative diameter B value for Group 1 was 22.5 ± 2.8 , while it was 27.5 ± 2.9 for Group 2. Postoperatively, the mean diameter B was 24.8 ± 2.5 for Group 1 and 29.3 ± 2.7 for Group 2, and it increased for each patient in both groups and increased statistically significantly ($p=0.001$). According to the diameter B change, the change in Group 1 was 2.31 ± 2.1 mm (95% CI: 1.92-2.71) and the change in Group 2 was 2.22 ± 2.3 mm (95% CI: 1.65-2.79). Although the difference between the two groups was not statistically significant ($p=0.78$), the diameter B in small necks was more expansive than in pre-aneurysmatic necks (Table 2). Considering the mean values, for Group 1, approximately 13.5% increase in diameter A and approximately 10.2% increase in diameter B were observed. For Group 2, an increase of approximately 10.5% was seen in diameter A and approximately 8.9% in diameter B.

Overall survival estimated by Kaplan-Meier analysis was 90% at one year, 82% at three years and 79% at five years. According to groups, survival estimation was 89% at one year, 84% at three years, 81% at five years for Group 1 and 91% at one year,

79% at three years, 76% at five years for Group 2, respectively.

Freedom from type 1 endoleak was 99% at one year, 95% at three years, 95% at five years for overall: 99% at one year, 97% at three years, 97% at five years for Group 1 and 100% at one year, 92% at three years, 92% at five years for Group 2, respectively.

Freedom from event was estimated as 89% at one year, 78% at three years, 75% at five years for overall: 88% at one year, 81% at three years, 78% at five years for Group 1 and 91% at one year, 72% at three years, 69% at five years for Group 2, respectively.

Cumulative Kaplan-Meier analysis with log-rank estimated no significant difference between the two groups in terms of type 1a endoleak-free survival ($p=0.24$), event-free survival ($p=0.26$), and overall survival ($p=0.54$) (Figure 2).

DISCUSSION

During the past decade, EVAR has gained wide acceptance as the preferred treatment method for patients with suitable AAAs.^[3] However, this method does not completely eliminate the risk of complications and mortality, and EVAR has its own risk of morbidity and mortality. Among the many risk factors identified for EVAR success and outcomes,^[8,9] the role of PIANd has been an important focus of attention.^[10-12] In the present study, the impact of preoperative PIANd on EVAR outcomes, as well as the effects of EVAR on PIANd, were examined. Our study results showed that pre-procedural normal or wide PIANd had no effect on post-EVAR complications, mortality, and survival. Significant PIANd enlargement after EVAR was observed independently of pre-EVAR PIANd values due to the oversizing issue of endovascular procedures as expected.

Identification of factors that may affect and predict post-EVAR mortality, adverse events such as leakage, graft migration, aneurysmal sack dilatation, and re-intervention may change the clinical decision regarding the choice of repair and the post-procedure surveillance management of high-risk patients. A healthy aortic sealing zone is the key factor linked to a lower incidence of these complications and higher procedural success. Large proximal aortic neck diameter is considered to be one of the factors affecting this zone.^[11] Although EVAR in patients with large aneurysm necks has been associated with an increased risk of neck-related adverse events in several studies,^[4,8,13] the overall understanding of EVAR outcomes in patients with large PIANds are

not adequately supported by the data. In the current study, the rates of endoleak, type 1a endoleak, and all-cause mortality rates were 16.8%, 2.7%, and 16.8%, respectively in Group 1, while these rates were 20.9%, 5.9%, and 20.9%, respectively in Group 2. No graft migration was observed in any of our patients. The cut-off value for large proximal aortic neck was accepted as ≥ 25 mm, as previously described in some studies.^[7,14,15] However, we observed that PIANd below or above this value had no effect on neither mortality, overall endoleak, and type 1a endoleak rate (over a mean follow-up time of 29.4 ± 11.7 months), nor six-year overall survival, type 1a endoleak-free survival, and event-free survival rates after EVAR. Aburahma et al.^[12] found no correlation between the aneurysm neck diameter and type 1a endoleaks or the need for a secondary aortic cuff. Similar results were also reported by Bastos Goncalves et al.,^[16] who found no increased risk of neck-related adverse events in 398 patients treated with 32- or 36-mm Endurant™ stent grafts. In contrast, many other reports have associated large infrarenal neck diameter to post-EVAR adverse outcomes and/or survival. In a multi-center, retrospective study, patients with a PIANd of ≥ 30 mm had more type 1 endoleaks than those with value of < 30 mm and large PIANd was an independent risk factor for neck-related adverse events, secondary interventions, and type 1 endoleak.^[8] Howard et al.^[4] reported that patients with a large proximal aortic neck had a higher rate of type 1a endoleaks and a lower five-year survival rate. In another study, Antoniou et al.^[17] compiled the results of nine studies that included 7,682 patients with AAAs, grouped as patients with large versus small aortic necks. The risk of death, aneurysm-related reintervention, type 1a endoleak, sac enlargement and aneurysm rupture were significantly higher in patients with a large proximal aortic neck than those with a small neck. Also, in some other studies, worse outcomes have been reported after EVAR procedures in patients with a large proximal aortic neck.^[5,9,13] The reasons for the discrepancy between the study results can be attributed to the differences in the accepted cut-off values for large PIANd, the procedures applied (e.g., oversizing percentages), endograft type, follow-up times, study population, and also, the operator. There are studies reporting that increased PIANd is not associated with increased complications after EVAR despite having a higher cut-off value for wide aneurysm,^[16] compared to other studies reporting that increased PIANd is associated with increased complications after EVAR.^[13,18-21] Therefore, we believe that the results obtained in our study may not be directly associated

with our cut-off value. Also, the compatibility of the graft with the aorta is critical for successful fixation and the prevention of both graft migration and type 1 endoleaks. The complication and mortality rates we obtained are compatible with the literature and may even be somewhat lower.^[10,20] Appropriate patient selection for EVAR is critical in this context.^[21] We believe that the early detection and treatment of type 1a endoleaks could be a factor that improved our results. Therefore, we would like to emphasize the importance of close patient follow-up in the early postoperative period. However, comprehensive randomized-controlled trials seem to be necessary to definitively show the effect of pre-EVAR PIAND values on EVAR outcomes.

The success and long-term durability of EVAR depends on successful sealing between the graft and the aneurysm neck. Gradual dilatation of the aortic neck after EVAR may result in loss of the seal, endoleak, migration, and need for secondary interventions.^[3,21] Neck dilatation following EVAR is a well-known occurrence, particularly in large size self-expanding endografts.^[20,22] It has been shown that pathologies in the infrarenal neck or continued aneurysmal disease may lead to progressive dilatation. Moreover, it may be a result of endografts radial force.^[23,24] Neck enlargement can be defined as dilatation of 3-mm or more between the first postoperative and last available CTA. The incidence of neck enlargement in all EVAR patients during two years of follow-up was 20%.^[21] Therefore, it is of utmost importance to elucidate the risk factors of neck enlargement to both increase the success of the procedure and minimize complications such as endoleak and graft migration. However, the causes of neck dilatation after EVAR are still debated.^[25] In this study, we also investigated whether pre-EVAR PIAND was associated with post-EVAR neck enlargement. We found that both diameter A and diameter B of the two groups increased significantly after the procedure. For Group 1, we observed approximately 13.5% increase in diameter A, while diameter B demonstrated approximately 10.2% increase. For Group 2, an increase of approximately 10.5% was seen in diameter A and approximately 8.9% in diameter B. Although there was more dilatation in patients with pre-EVAR <25-mm proximal necks, there was no significant difference between the groups in terms of increase in neither diameter. One study compared the PIAND changes after EVAR in patients with a PIAND of ≥ 30 mm and those with a PIAND less than 30 mm. While the PIAND enlargement was 4.3 mm in the >30-mm group, this number was reported as 3 mm

in the <30-mm group. However, similar to our study, this difference was not significant.^[20] Other similar studies have also shown that pre-EVAR PIAND is not associated with post-EVAR proximal neck enlargement.^[21-25] Diameter changes of the proximal neck after EVAR have been investigated in several studies which obtained varying results. Diehm *et al.*^[26] reported a >15% increase in proximal neck diameter in 24.9% of patients at two-year follow-up and in 35.1% of patients at four-year follow-up. On the other hand, some researchers have argued that there is no enlargement of the aneurysm neck diameter after EVAR.^[27,28]

Another issue is the clinical significance of aortic neck dilatation. This issue is still controversial,^[3] as some studies have argued that proximal neck enlargement is correlated with migration and endoleak type 1, while others have claimed that there is no relationship between the two conditions.^[5,21,29] The 10 to 20% oversizing regimen was suggested as a safe range in the literature^[30] and, therefore, we applied a maximum of 20% oversizing in our patients. The amount of dilatation in proximal neck diameter we obtained is compatible with the literature.^[20] However, with the available data, it is unclear whether enlargement is associated with pre-EVAR PIAND values, oversizing, or complications. We believe that further comprehensive studies would elucidate these relationships.

As a result, although the causes and clinical significance of proximal neck enlargement after EVAR are not fully known, pre-EVAR PIAND does not seem to be related to this enlargement. We believe that the most important reason for obtaining literature-compatible results (regarding diameter changes in PIAND) in this study is the application of appropriate oversizing.

Nonetheless, there are some limitations to this study. First, this study is limited in its generalizability due to its single-center design, which may not be representative of other populations. Second, the study is retrospective in nature, which may have introduced biases in data collection and analysis. Third, the difference in sample sizes between groups may have affected the reliability of statistical evaluations. Additionally, the mean follow-up times are relatively short, which limits the ability to make long-term interpretations. Furthermore, the difference in follow-up periods among patients is another important limitation. The decrease in elective cases during the novel coronavirus disease 2019 (COVID-19) period or the fact that patients did not come for control limited

the number of patients. Therefore, the number of patients decreased at that time. Finally, the study only presents the latest values obtained, without showing the stages of dilatation in the proximal neck. This could have led to changes in enlargement between groups at later follow-ups.

In conclusion, pre-endovascular aortic repair proximal infrarenal aortic neck diameter over 25 mm within the anatomical suitability limits may not have an effect on post-endovascular aortic repair dilatation and its outcomes. Based on these findings, we suggest that endovascular aortic repair outcomes can be improved with careful patient selection, graft and oversizing selection, and early intervention for complications, and further research is needed to determine the potential impact of pre-endovascular aortic repair proximal infrarenal aortic neck diameter on endovascular aortic repair outcomes and the clinical significance of proximal neck enlargement after endovascular aortic repair.

Ethics Committee Approval: The study protocol was approved by the Ankara City Hospital Clinical Research Ethics Committee (date: 14.10.2020, no: E1-20-1217). The study was conducted in accordance with the principles of the Declaration of Helsinki.

Patient Consent for Publication: A written informed consent was obtained from each patient.

Data Sharing Statement: The data that support the findings of this study are available from the corresponding author upon reasonable request.

Author Contributions: Idea/concept, B.A., G.D., F.C., SM, N.B.T., E.U.U., A.B.D., H.Z.I.; Design, B.A., G.D., F.C., SM, N.B.T., E.U.U., A.B.D., H.Z.I.; Control/supervision, B.A., G.D., F.C., SM, N.B.T., E.U.U., A.B.D., H.Z.I.; Data collection and/or processing, B.A., G.D., F.C., S.M., N.B.T., H.Z.I.; Analysis and/or interpretation, B.A., G.D., F.C., SM, N.B.T., E.U.U., A.B.D., H.Z.I.; Literature review, B.A., G.D., F.C., S.M., N.B.T.; Writing the article B.A., G.D., F.C., SM, N.B.T., E.U.U., A.B.D., H.Z.I.; Critical review, B.A., G.D., E.U.U., H.Z.I.; References and fundings, B.A., G.D., F.C.; Materials, B.A., G.D., F.C.; Other, B.A., G.D., S.M., A.B.D. All authors have read and agreed to the published version of the manuscript.

Conflict of Interest: The authors declared no conflicts of interest with respect to the authorship and/or publication of this article.

Funding: The authors received no financial support for the research and/or authorship of this article.

REFERENCES

1. Prinssen M, Verhoeven EL, Buth J, Cuypers PW, van Sambeek MR, Balm R, et al. A randomized trial comparing conventional and endovascular repair of abdominal aortic aneurysms. *N Engl J Med* 2004;351:1607-18. doi: 10.1056/NEJMoa042002.
2. İşcan HZ, Karahan M, Akkaya BB, Başar V, Aşkın G, Kubat E, et al. Long-term results of endovascular intervention with unibody bifurcation endograft for elective abdominal aortic aneurysm management. *Rev Cardiovasc Med* 2021;22:453-9. doi: 10.31083/j.rcm2202051.
3. Kouvelos GN, Oikonomou K, Antoniou GA, Verhoeven EL, Katsargyris A. A systematic review of proximal neck dilatation after endovascular repair for abdominal aortic aneurysm. *J Endovasc Ther* 2017;24:59-67. doi: 10.1177/1526602816673325.
4. Howard DPJ, Marron CD, Sideso E, Puckridge PJ, Verhoeven ELG, Spark JI; Global Registry for Endovascular Aortic Treatment (GREAT) Investigators. Editor's choice - influence of proximal aortic neck diameter on durability of aneurysm sealing and overall survival in patients undergoing endovascular aneurysm repair. Real world data from the Gore Global Registry for Endovascular Aortic Treatment (GREAT). *Eur J Vasc Endovasc Surg* 2018;56:189-99. doi: 10.1016/j.ejvs.2018.03.027.
5. Napoli V, Sardella SG, Bargellini I, Petrucci P, Cioni R, Vignali C, et al. Evaluation of the proximal aortic neck enlargement following endovascular repair of abdominal aortic aneurysm: 3-years experience. *Eur Radiol* 2003;13:1962-71. doi: 10.1007/s00330-003-1859-y.
6. van Prehn J, Schlösser FJ, Muhs BE, Verhagen HJ, Moll FL, van Herwaarden JA. Oversizing of aortic stent grafts for abdominal aneurysm repair: A systematic review of the benefits and risks. *Eur J Vasc Endovasc Surg* 2009;38:42-53. doi: 10.1016/j.ejvs.2009.03.025.
7. Lindholt JS, Vammen S, Juul S, Fasting H, Henneberg EW. Optimal interval screening and surveillance of abdominal aortic aneurysms. *Eur J Vasc Endovasc Surg* 2000;20:369-73. doi: 10.1053/ejvs.2000.1191.
8. AbuRahma AF, Yacoub M, Mousa AY, Abu-Halimah S, Hass SM, Kazil J, et al. Aortic neck anatomic features and predictors of outcomes in endovascular repair of abdominal aortic aneurysms following vs not following instructions for use. *J Am Coll Surg* 2016;222:579-89. doi: 10.1016/j.jamcollsurg.2015.12.037.
9. Oliveira NFG, Gonçalves FB, Ultee K, Pinto JP, Josee van Rijn M, Raa ST, et al. Patients with large neck diameter have a higher risk of type IA endoleaks and aneurysm rupture after standard endovascular aneurysm repair. *J Vasc Surg* 2019;69:783-91. doi: 10.1016/j.jvs.2018.07.021.
10. Kouvelos GN, Spanos K, Nana P, Koutsias S, Rousas N, Giannoukas A, et al. Large diameter (≥ 29 mm) proximal aortic necks are associated with increased complication rates after endovascular repair for abdominal aortic aneurysm. *Ann Vasc Surg* 2019;60:70-5. doi: 10.1016/j.avsg.2019.02.031.
11. Antoniou GA, Georgiadis GS, Antoniou SA, Kuhan G, Murray D. A meta-analysis of outcomes of endovascular abdominal aortic aneurysm repair in patients with hostile and friendly neck anatomy. *J Vasc Surg* 2013;57:527-38. doi: 10.1016/j.jvs.2012.09.050.

12. Aburahma AF, Campbell JE, Mousa AY, Hass SM, Stone PA, Jain A, et al. Clinical outcomes for hostile versus favorable aortic neck anatomy in endovascular aortic aneurysm repair using modular devices. *J Vasc Surg* 2011;54:13-21. doi: 10.1016/j.jvs.2010.12.010.
13. Waasdorp EJ, de Vries JP, Hobo R, Leurs LJ, Buth J, Moll FL; EUROSTAR Collaborators. Aneurysm diameter and proximal aortic neck diameter influence clinical outcome of endovascular abdominal aortic repair: A 4-year EUROSTAR experience. *Ann Vasc Surg* 2005;19:755-61. doi: 10.1007/s10016-005-7971-5.
14. Devaraj S, Dodds SR. Ultrasound surveillance of ectatic abdominal aortas. *Ann R Coll Surg Engl* 2008;90:477-82. doi: 10.1308/003588408X301064.
15. Thompson SG, Ashton HA, Gao L, Buxton MJ, Scott RA; Multicentre Aneurysm Screening Study (MASS) Group. Final follow-up of the Multicentre Aneurysm Screening Study (MASS) randomized trial of abdominal aortic aneurysm screening. *Br J Surg* 2012;99:1649-56. doi: 10.1002/bjs.8897.
16. Bastos Goncalves F, Hoeks SE, Teijink JA, Moll FL, Castro JA, Stolker RJ, et al. Risk factors for proximal neck complications after endovascular aneurysm repair using the enduring stentgraft. *Eur J Vasc Endovasc Surg* 2015;49:156-62. doi: 10.1016/j.ejvs.2014.10.003.
17. Antoniou GA, Alfahad A, Antoniou SA, Badri H. Prognostic significance of large diameter proximal aortic neck in endovascular aneurysm repair. *Vasa* 2020;49:215-24. doi: 10.1024/0301-1526/a000844.
18. Stather PW, Sayers RD, Cheah A, Wild JB, Bown MJ, Choke E. Outcomes of endovascular aneurysm repair in patients with hostile neck anatomy. *Eur J Vasc Endovasc Surg* 2012;44:556-61. doi: 10.1016/j.ejvs.2012.10.003.
19. Jim J, Rubin BG, Geraghty PJ, Criado FJ, Fajardo A, Sanchez LA. A 5-year comparison of EVAR for large and small aortic necks. *J Endovasc Ther* 2010;17:575-84. doi: 10.1583/10-3140.1.
20. Oliveira NFG, Bastos Gonçalves FM, Van Rijn MJ, de Ruiter Q, Hoeks S, de Vries JPM, et al. Standard endovascular aneurysm repair in patients with wide infrarenal aneurysm necks is associated with increased risk of adverse events. *J Vasc Surg* 2017;65:1608-16. doi: 10.1016/j.jvs.2016.09.052.
21. Dillavou ED, Muluk S, Makaroun MS. Is neck dilatation after endovascular aneurysm repair graft dependent? Results of 4 US Phase II trials. *Vasc Endovascular Surg* 2005;39:47-54. doi: 10.1177/153857440503900105.
22. Sampaio SM, Panneton JM, Mozes G, Andrews JC, Noel AA, Kalra M, et al. Aortic neck dilation after endovascular abdominal aortic aneurysm repair: Should oversizing be blamed? *Ann Vasc Surg* 2006;20:338-45. doi: 10.1007/s10016-006-9067-2.
23. Diehm N, Di Santo S, Schaffner T, Schmidli J, Völzmann J, Jüni P, et al. Severe structural damage of the seemingly non-diseased infrarenal aortic aneurysm neck. *J Vasc Surg* 2008;48:425-34. doi: 10.1016/j.jvs.2008.03.001.
24. İşcan HZ, Ünal EU, Tümer NB, Akkaya BB, Aşkın G, Sağlam S, et al. Funnel technique for wide infrarenal aneurysm neck with Lifetech Ankura™ Stent Graft System. *Turk Gogus Kalp Damar Cerrahi Derg* 2021;29:304-10. doi: 10.5606/tgkdc.dergisi.2021.21183.
25. Makaroun MS, Deaton DH. Is proximal aortic neck dilatation after endovascular aneurysm exclusion a cause for concern? *J Vasc Surg* 2001;33(2 Suppl):S39-45. doi: 10.1067/mva.2001.111679.
26. Diehm N, Hobo R, Baumgartner I, Do DD, Keo HH, Kalka C, et al. Influence of pulmonary status and diabetes mellitus on aortic neck dilatation following endovascular repair of abdominal aortic aneurysms: A EUROSTAR report. *J Endovasc Ther* 2007;14:122-9. doi: 10.1177/152660280701400202.
27. Malas MB, Ohki T, Veith FJ, Chen T, Lipsitz EC, Shah AR, et al. Absence of proximal neck dilatation and graft migration after endovascular aneurysm repair with balloon-expandable stent-based endografts. *J Vasc Surg* 2005;42:639-44. doi: 10.1016/j.jvs.2005.06.017.
28. Peirano MA, Bertoni HG, Chikiar DS, Martínez JM, Girella GA, Barone HD, et al. Size of the proximal neck in AAAs treated with balloon-expandable stent-grafts: CTA findings in mid- to long-term follow-up. *J Endovasc Ther* 2009;16:696-707. doi: 10.1583/09-2711.1.
29. Savlovskis J, Krievins D, de Vries JP, Holden A, Kisis K, Gedins M, et al. Aortic neck enlargement after endovascular aneurysm repair using balloon-expandable versus self-expanding endografts. *J Vasc Surg* 2015;62:541-9. doi: 10.1016/j.jvs.2015.04.393.
30. Malach L, Tehrani N, Kolachina S, Krawczyk K, Wozniak A, Soult M, et al. Effect of stent-graft active fixation and oversizing on aortic neck dilatation after endovascular aneurysm exclusion for infrarenal aortic aneurysm. *Ann Vasc Surg* 2022;79:100-5. doi: 10.1016/j.avsg.2021.08.026.