

Multidisciplinary treatment for a patient with Pentalogy of Cantrell in the COVID-19 pandemic

COVID-19 pandemisinde Cantrell pentalojisi olan bir hasta için multidisipliner tedavi

Mustafa Karaçelik¹, Akgün Oral², Çağatay Bilen¹, Kamer Polatdemir²

Author Affiliations:

¹Department of Pediatric Cardiac Surgery, Health Sciences University, Izmir Dr. Behçet Uz Children's Hospital, Izmir, Türkiye

²Department of Pediatric Surgery, Health Sciences University, Izmir Dr. Behçet Uz Children's Hospital, Izmir, Türkiye

ABSTRACT

In this article, we present a multidisciplinary approach for the treatment of a patient with Pentalogy of Cantrell, dextrocardia, perimembranous ventricular septal defect, secundum atrial septal defect, pulmonary valvular stenosis, and left ventricle diverticulum during the novel coronavirus disease 2019 (COVID-19) pandemic.

Keywords: COVID-19, multidisciplinary treatment, Pentalogy of Cantrell.

Pentalogy of Cantrell (POC) was first described by Cantrell et al.^[1] in 1958 as a rare syndrome. Without a genetic mutation, it has five components, including the diaphragm, abdominal wall, lower sternum, pericardium, and heart defects.^[1] The most common accompanying defect is the ventricular septal defect (VSD), although its incidence has been decreasing recently, and atrial septal defect (ASD), pulmonary stenosis (PS), Tetralogy of Fallot (TOF), and left ventricular diverticulum are commonly seen. The presence of cardiac ectopy, dextrocardia, and left ventricle diverticulum originating from the left ventricle are major challenges. In particular, the severity of the cardiac defect is a determinant factor for the prognosis of the disease.^[2]

During the novel coronavirus disease 2019 (COVID-19) pandemic, there have been difficulties in the timing and treatment of congenital heart surgery interventions all over the world. Therefore, medical

ÖZ

Bu yazıda yeni koronavirus hastalığı 2019 (COVID-19) pandemisi sırasında Cantrell pentalojisi, dekstrocardi, perimembranöz ventriküler septal defekt, sekundum atriyal septal defekt, pulmoner kapak darlığı ve sol ventrikül divertikülü olan bir hastanın tedavisi için multidisipliner bir yaklaşım sunuldu.

Anahtar sözcükler: COVID-19, multidisipliner tedavi, Cantrell pentalojisi.

follow-up of patients whose surgical treatment is complex should be done with care and attention during the pandemic period.^[3] In this article, we present the treatment process of a patient with POC, VSD, pulmonary valve stenosis, and left ventricular diverticulum with a multidisciplinary approach during the COVID-19 pandemic.

CASE REPORT

A female newborn with a complete form of POC and multiple congenital cardiac anomalies was referred to our hospital. On physical examination, no additional pathology was observed, except for a 3/6 systolic murmur in the left anterior region of the sternum, and a large supraumbilical hernia with a pulsation of the diverticulum starting from the lower part of the sternum and extending to the umbilicus (Figure 1). In-room oxygen saturation was within the range of 85 to 95%. Echocardiography demonstrated dextrocardia,

Corresponding author: Mustafa Karaçelik.

E-mail: mkaracelik@hotmail.com

Doi: 10.5606/tgkdc.dergisi.2024.24969

Received: March 28, 2023

Accepted: July 27, 2023

Published online: November 06, 2023

Cite this article as: Karaçelik M, Oral A, Bilen Ç, Polatdemir K. Multidisciplinary treatment for a patient with Pentalogy of Cantrell in the COVID-19 pandemic. Turk Gogus Kalp Dama 2024;32(x):1-4. doi: 10.5606/tgkdc.dergisi.2024.24969.

©2024 All right reserved by the Turkish Society of Cardiovascular Surgery.



This is an open access article under the terms of the Creative Commons Attribution-NonCommercial License, which permits use, distribution and reproduction in any medium, provided the original work is properly cited and is not used for commercial purposes (<http://creativecommons.org/licenses/by-nc/4.0/>).

a 7-mm VSD, a 4-mm secundum ASD, pulmonary valvular stenosis with a peak gradient of 40 mmHg, and a 5×5-cm omphalocele-related left ventricular diverticulum. The initial evaluation was made by cardiac surgeons, pediatric surgeons, and cardiologists on Day 3 after birth. It was decided that waiting for the epithelialization of the omphalocele sac was more appropriate for both the risk of the abdominal compartment and the success of cardiac surgery without any topical medication. In addition, it was considered that the presence of PS in the patient would prevent pulmonary hypertension, and the operation was planned to be performed at six months of life. However, due to the COVID-19 pandemic lockdown that started at the end of 2020, surgery was postponed again and the patient was followed closely by the Department of Pediatric Cardiology. The patient who was followed for 18 months was hospitalized for an operation, as pulmonary hypertension was not observed in the catheter angiography performed and the reversibility

test was positive and not indicative of pulmonary hypertension. A preoperative planning meeting was held. After repairing the diaphragm via intervention in the omphalocele sac by pediatric surgeons following sternotomy, it was planned to initiate cardiopulmonary bypass (CPB) to reduce the duration of time the patient spent under the aortic clamp.

The patient underwent a multidisciplinary surgery involving both pediatric surgery and congenital heart surgery teams. After the median sternotomy under general anesthesia, the skin incision was extended to the umbilicus. The lower one-third of the sternum did not develop. The 5×5-cm diverticulum originating from the left ventricle was adhered to the pericardium and passed through the defect in the diaphragm. At this point, under the pediatric surgeon's discretion, the diverticulum was separated from all adherent tissues. The ileum and transverse colon passing through the diaphragmatic defect were reduced to the abdominal cavity. The diaphragm and abdominal defect were

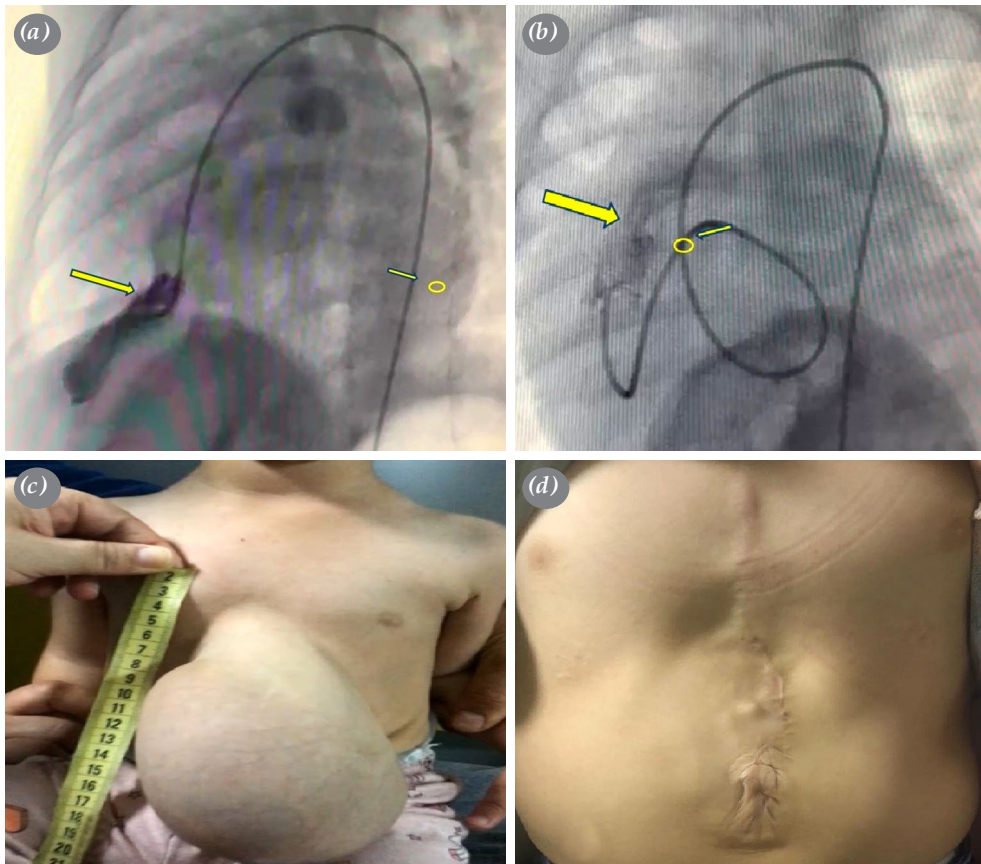


Figure 1. (a) Angiographic view of the left ventricular diverticulum. (b) Angiographic view of pulmonary valve stenosis. The catheter was routed to the right ventricle via a trans-ventricular septal defect. (c) Preoperative view of the chest and abdominal midline defect. (d) The image of the postoperative surgical scar.

primarily repaired. Heart surgeons took over control at this stage, and after systemic intravenous heparinization, aorticaval cannulation was applied. The CPB was started. A cross-clamp was placed on the aorta at 32°C. The diastolic arrest was achieved after antegrade cold blood cardioplegia, and the left ventricle diverticulum was excised. The defect in the left ventricle was repaired using polytetrafluoroethylene (PTFE) felt support. After the right atriotomy, the perimembranous VSD was closed with PTFE pledgeted 5.0 polypropylene interrupted sutures using a bovine pericardial patch. After pulmonary arteriotomy, valvuloplasty was performed on the bicuspid pulmonary valve. The

pulmonary arteriotomy was closed primarily. The CPB was completed uneventfully. The upper two-third of the sternum was closed by sternal wires, whereas the defect in the lower one-third of the sternum was closed using a 0.6-mm PTFE patch with secondary intention. The entire skin defect was repaired and the patient was taken to the intensive care unit (Figure 2). The patient was extubated at 16 h postoperatively. After an uneventful early postoperative period, the patient was discharged on Day 6 without any wound problems. Subsequent echocardiographic follow-ups in pediatric cardiology revealed no issues. At 18 months of follow-up, the results were satisfactory.

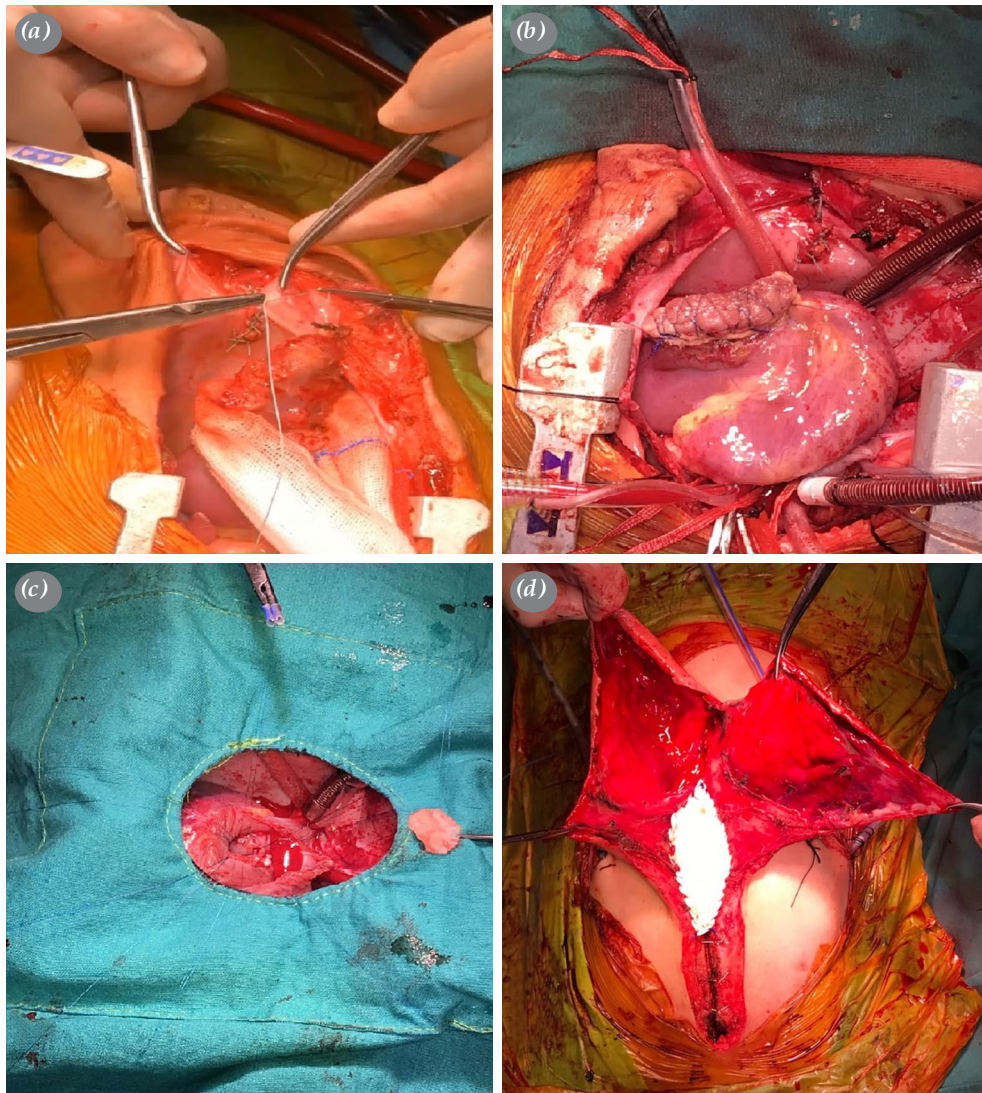


Figure 2. (a) Primary repair of the diaphragmatic defect. (b) Excision and repair of the left ventricular diverticulum. (c) Perimembranous ventricular septal defect closure. (d) Repair of sternum defect.

DISCUSSION

Pentalogy of Cantrell is a rare congenital syndrome that may present with various anatomical abnormalities affecting the abdominal wall, sternum, diaphragm, pericardium, and heart.^[1] Management of patients with POC can be challenging, particularly during the COVID-19 pandemic, as in this case. In our case, although the planned operation was delayed, we were able to perform a successful surgery after a thorough multidisciplinary approach.

The treatment of POC involves a single session or multiple operations, depending on the severity and extent of the anomalies.^[3] Preoperative planning and coordination among the surgical teams are crucial for a successful outcome, as was the case with our patient. We significantly reduced the time spent under aortic clamping by performing diaphragm repair and omphalocele sac intervention before CPB.

Due to the complex nature of the cardiac pathologies observed in POC, it is advisable to postpone treatment until a confirmed diagnosis is obtained, and a more effective and safer surgical approach can be employed.^[1] Our patient did not exhibit the main prognostic factor of cardiac ectopy. According to Aydın et al.,^[4] postponing surgery rather than operating immediately could improve postoperative outcomes. In their report of a pediatric case with POC and single ventricle physiology, a multidisciplinary approach was also employed.

The available literature on POC suggests that surgical intervention should be delayed until a definitive diagnosis is made and a safe surgical approach can be planned. Waiting for the diagnosis to be confirmed improves postoperative results. However, the timing of surgery in cases of cardiac diverticulum is still controversial, and no clear consensus has been reached on the optimal timing of surgery. In general, the timing of surgery for the cardiac diverticulum depends on the size and location of the diverticulum, as well as the presence of associated anomalies. A multidisciplinary approach is necessary to evaluate each case individually and determine the optimal timing of surgery.^[4] In their study, Halbertsma et al.^[5] discussed the significance of early surgical intervention due to potential complications related to the ventricular

diverticulum. They presented a case study of a neonate with concurrent omphalocele and left ventricular diverticulum, which strongly indicated POC with ectopia cordis being the most severe malformation.

In conclusion, the management of patients with Pentalogy of Cantrell requires a thorough multidisciplinary approach and careful evaluation of each case individually. In our experience, performing surgery during the infancy period instead of the newborn period may lead to better postoperative outcomes.

Patient Consent for Publication: A written informed consent was obtained from the parent of the patient.

Data Sharing Statement: The data that support the findings of this study are available from the corresponding author upon reasonable request.

Author Contributions: Idea/concept, writing the article: M.K.; Design: M.K., Ç.B.; Control/supervision: M.K., A.O.; Data collection, references: K., Ç.B.; Literature review: Ç.B.

Conflict of Interest: The authors declared no conflicts of interest with respect to the authorship and/or publication of this article.

Funding: The authors received no financial support for the research and/or authorship of this article.

REFERENCES

1. Cantrell JR, Haller JA, Ravitch MM. A syndrome of congenital defects involving the abdominal wall, sternum, diaphragm, pericardium, and heart. *Surg Gynecol Obstet* 1958;107:602-14.
2. Vazquez-Jimenez JF, Muehler EG, Daebritz S, Keutel J, Nishigaki K, Huegel W, et al. Cantrell's syndrome: A challenge to the surgeon. *Ann Thorac Surg* 1998;65:1178-85. doi: 10.1016/s0003-4975(98)00089-7.
3. Korun O, Yurdakök O, Arslan A, Çiçek M, Selçuk A, Kılıç Y, et al. The impact of COVID-19 pandemic on congenital heart surgery practice: An alarming change in demographics. *J Card Surg* 2020;35:2908-12. doi: 10.1111/jocs.14914.
4. Aydın S, Suzan D, Çevik M, Ödemiş E, Ereğ E. Univentricular heart and Cantrell syndrome in a pediatric case. *Turk Gogus Kalp Dama* 2016;24:542-4.
5. Halbertsma FJ, van Oort A, van der Staak F. Cardiac diverticulum and omphalocele: Cantrell's pentalogy or syndrome. *Cardiol Young* 2002;12:71-4. doi: 10.1017/s1047951102000148.