

Coronary cameral fistula in a Fontan physiology patient with pulmonary atresia and intact ventricular septum: Should it be closed?

Fontan fiziolojisindeki intakt ventriküler septumlu ve pulmoner atrezili hastada koroner kameral fistül: Kapatılmalı mıdır?

Ensar Duras , Perver Arslan , Selman Gokalp , Alper Guzeltaş 

Department of Pediatric Cardiology, University of Health Sciences,
Mehmet Akif Ersoy Chest Cardiovascular Surgery Training and Research Hospital, Istanbul, Türkiye

In patients with pulmonary atresia with intact ventricular septum (PA/IVS), coronary anomalies are frequently observed, particularly in cases where the right ventricular cavity is diminutive and hypertrophic.^[1] Fistulas between the right ventricle and coronary arteries are commonly observed, with a frequency ranging from 31 to 68%.^[2] In the presence of coronary cameral fistula, coronary artery blood flow can be either directed into the right ventricle or be bidirectional. Surgical decompression of the right ventricle may pose a potential risk when associated with the development of coronary steal phenomenon and myocardial ischemia. Herein, the management of a coronary cameral fistula detected in a patient with Fontan physiology and no evidence of ischemia was presented.

A 13-year-old male patient who previously underwent neonatal modified Blalock-Taussig shunt insertion, superior cavopulmonary connection, and, finally, the Fontan procedure (at the age of six years) without right ventricular decompression in another hospital presented to the clinic. During the routine echocardiographic examination performed in our center, the patient was diagnosed with coronary cameral fistula (Figure 1). The patient only experienced mild chest pain after intense exertion and had stable vital signs. Electrocardiogram did not show any signs of ischemic change, and serum levels of troponin I, CK-MB (creatin kinase-myocardial band), and NT-proBNP (N-terminal pro-

brain natriuretic peptide) were normal. The patient reached Stage 4 in the exercise treadmill test using a modified Bruce protocol without ischemic changes on the electrocardiogram. Cardiac catheterization revealed a normal origin and course of the left main

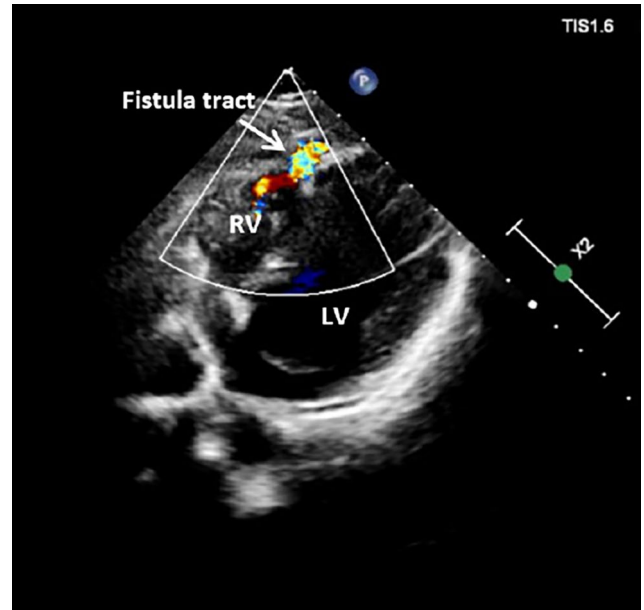


Figure 1. An echocardiographic view shows a coronary fistula originating from the anterior aspect of the right ventricle and draining into the hypoplastic right ventricle.

LV: Left ventricle; RV: Right ventricle.

Corresponding author: Ensar Duras.

E-mail: ensarduras@gmail.com

Doi: 10.5606/tgkdc.dergisi.2024.25827

Received: December 07, 2023

Accepted: March 05, 2024

Published online: July 23, 2024

Cite this article as: Duras E, Arslan P, Gokalp S, Guzeltaş A. Coronary cameral fistula in a Fontan physiology patient with pulmonary atresia and intact ventricular septum: Should it be closed? Turk Gogus Kalp Dama 2024;32(3):343-345. doi: 10.5606/tgkdc.dergisi.2024.25827.

©2024 All right reserved by the Turkish Society of Cardiovascular Surgery.



This is an open access article under the terms of the Creative Commons Attribution-NonCommercial License, which permits use, distribution and reproduction in any medium, provided the original work is properly cited and is not used for commercial purposes (<http://creativecommons.org/licenses/by-nc/4.0/>).

coronary artery, giving rise to the circumflex and left anterior descending (LAD) branches. The LAD was dilated throughout its course, with a diameter gradually increasing up to 10 mm in the middle portion and then gradually becoming thinner distally, following a tortuous path. The fistula drained into the severely hypoplastic right ventricle through a slit-like orifice. A small amount of contrast material passed into the hypoplastic right ventricle through the significantly narrowed distal part of the fistula tract. A thin fistula tract opening into the right ventricle was also observed at the distal part of the first diagonal branch of LAD (Figure 2). Cardiac computed tomography (CT) angiography confirmed the presence of a tortuous fistula tract between the distal segment of the LAD artery and the apex of the right ventricle, with a diameter of 2.3 mm in the middle section and 4.3 mm at the right ventricular junction. According to the cardiac CT findings, the origin and course of the right coronary artery were normal (Figure 3). Cardiac magnetic resonance imaging showed no myocardial fibrosis and normal left ventricular function.

In angiography via the fistula tract, our patient showed no evidence of coronary steal phenomenon attributed to the distal stenosis in the fistula. Therefore, the procedure was terminated, as there was no indication of closing the coronary fistula, particularly considering

the high oxygen saturation (99%) measured from the blood gas obtained through the fistula tract.

Pulmonary atresia with intact ventricular septum encompasses a broad spectrum of variability in the size and morphology of the right ventricle. In cases where the right ventricle is undeveloped and hypertrophic (unipartite right ventricle), the presence of coronary cameral fistulas with or without right ventricular dependence can be identified. In right ventricle-dependent coronary circulation (RVDCC), these connections with low-pressure compartments decompress the right ventricle. However, if there is a coronary fistula, this decompression could lead to a coronary steal phenomenon, or in the presence of coronary stenosis, it may cause ischemia.^[3]

In our patient, a coronary cameral fistula was observed during Fontan follow-ups. It remains unclear whether symptoms, particularly those occurring with exertion, result from increased tricuspid insufficiency due to geometric changes in the heart following the Fontan procedure, new-onset ischemia during surgical procedures, or as a consequence of the right ventricular steal phenomenon. Therefore, in patients who have undergone the Fontan procedure with PA/IVS, particularly if the patient is symptomatic, the coronary fistula should be investigated to determine whether any of these mechanisms are involved.

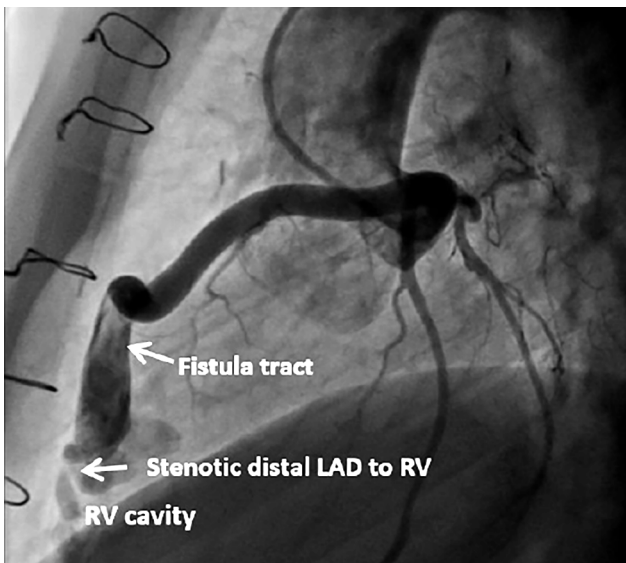


Figure 2. An angiographic view illustrates the path of the fistula and the narrowing in the region where it enters the right ventricular cavity.

RV: Right ventricle; LAD: Left anterior descending artery.

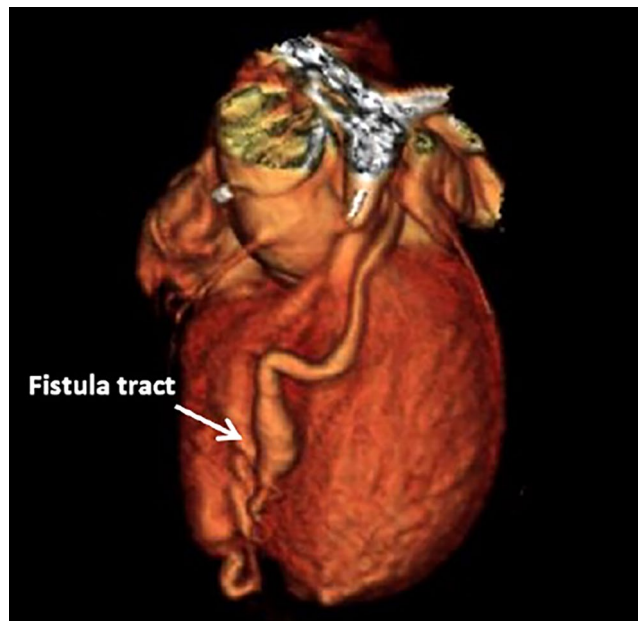


Figure 3. Three-dimensional volume-rendered image of the coronary fistula on computed tomography angiography.

In the presence of coronary steal phenomenon or signs of ischemia, resolution can be sought through catheterization or surgical methods. In a young case with evidence of myocardial ischemia secondary to the right ventricular steal phenomenon in the literature, successful closure of the fistula using a transcatheter method has been reported.^[4]

Coronary-ventricular connections carry a risk of coronary steal with ischemia in patients with pulmonary atresia with intact ventricular septum. In cases where a stenosis is found in the fistula tract and the patient remains asymptomatic, the decision not to close it may be considered.

Patient Consent for Publication: The patient's family provided written permission for the case report and any related photos to be published.

Data Sharing Statement: The data that support the findings of this study are available from the corresponding author upon reasonable request.

Author Contributions: Concept: E.D., P.A., S.G., A.G.; Design: E.D., S.G.; Data collection and processing: E.D., P.A.; Analysis or Interpretation: E.D., S.G., A.G.; Literature search: E.D., P.A., S.G., A.G.; Writing: E.D., S.G.

Conflict of Interest: The authors declared no conflicts of interest with respect to the authorship and/or publication of this article.

Funding: The authors received no financial support for the research and/or authorship of this article.

REFERENCES

1. Calder AL, Peebles CR, Occleshaw CJ. The prevalence of coronary arterial abnormalities in pulmonary atresia with intact ventricular septum and their influence on surgical results. *Cardiol Young* 2007;17:387-96. doi: 10.1017/S1047951107000893.
2. Freedom RM, Anderson RH, Perrin D. The significance of ventriculo-coronary arterial connections in the setting of pulmonary atresia with an intact ventricular septum. *Cardiol Young* 2005;15:447-68. doi: 10.1017/S1047951105001319.
3. Powell AJ, Mayer JE, Lang P, Lock JE. Outcome in infants with pulmonary atresia, intact ventricular septum, and right ventricle-dependent coronary circulation. *Am J Cardiol* 2000;86:1272-4, A9. doi: 10.1016/s0002-9149(00)01220-0.
4. Hope SA, Menahem S, Meredith IT. Transcatheter coil occlusion of coronary artery to right ventricular fistulae in pulmonary atresia with intact ventricular septum. *Heart Lung Circ* 2004;13:195-7. doi: 10.1016/j.hlc.2004.03.016.