

Surgical ablation of atrial fibrillation: Rationale and technique

Atriyal fibrilasyonun cerrahi ablasyonu: Bilimsel zemin ve teknik

Stephen D. Waterford¹, Niv Ad²

Institution where the research was done:

For institution, it is University of Pittsburgh Medical Center, Pittsburgh, USA

Author Affiliations:

¹Department of Cardiothoracic Surgery, Division of Cardiac Surgery University of Pittsburgh Medical Center, Pittsburgh, USA

²Department of Surgery, Division of Cardiac Surgery, Johns Hopkins University, Baltimore, USA

ABSTRACT

The Cox maze procedure is the most effective treatment for atrial fibrillation with the best long-term success rate compared to any other treatment modality, particularly in persistent and long-standing persistent atrial fibrillation. Cardiac surgeons have an unparalleled opportunity to treat atrial fibrillation as a concomitant operation during the treatment of ischemic or valvular disease. In addition, there are many options for surgical ablation of atrial fibrillation. In this review, we share the anatomic basis for surgical atrial fibrillation ablation, focusing on the Cox maze procedure and discuss some key technical points and common pitfalls to provide an effective ablation of atrial fibrillation. These include a discussion of avoidance of pacemaker implantation and other complications, and also how to produce the most effective lesions from a rhythm standpoint.

Keywords: Atrial fibrillation, maze procedure, surgical ablation.

Atrial fibrillation (AF) currently affects over 37.5 million people worldwide.^[1] It is estimated that it will affect 6 to 12 million individuals in the United States alone by 2050, and 17.9 million individuals in Europe by 2060.^[1] Furthermore, more than one million cardiac surgical procedures are performed each year globally.^[2] Given that AF affects one-third of those with mitral valve disease, and a lower but substantial fraction of those with coronary disease and aortic valve disease, there are now increasing opportunities for surgeons to provide definitive treatment for AF. In this review, we discuss the anatomic basis for some aspects of the

ÖZ

Cox maze işlemi, özellikle persistan ve uzun süreli persistan atriyal fibrilasyonun tedavisinde diğer tedavi yöntemlerine kıyasla uzun dönem başarı oranı ile en etkili tedavidir. Kalp cerrahları atriyal fibrilasyonu iskemik veya kapak hastalığının tedavisi sırasında eş zamanlı olarak tedavi etme konusunda benzersiz bir fırsata sahiptir. Bununla birlikte, atriyal fibrilasyonun cerrahi ablasyonu için birçok seçenek bulunmaktadır. Bu derlemede, Cox maze işlemine odaklanarak cerrahi atriyal fibrilasyon ablasyonunun anatomik temeli paylaşılmış, etkili ablasyon için bazı önemli teknik noktalar ve yaygın tuzaklar irdelenmiştir. Kalp pili implantasyonunun ve diğer komplikasyonların önlenmesi ile ritim açısından en etkili lezyonların nasıl üretileceği konusundaki tartışmalara yer verilmiştir.

Anahtar sözcükler: Atriyal fibrilasyon, maze işlemi, cerrahi ablasyon.

maze procedure and spend the majority of the review discussing technical aspects of arrhythmia surgery.

MAZE PROCEDURE

Following extensive research using animal models with AF and human mapping, the maze procedure was developed based on the creation of a three-dimensional (3D) maze that was designed to interrupt multiple macro-reentrant circuits. Dr. James Cox placed lines on a model of the atrium which would permit the electrical activity of the heart to be conducted from the sinoatrial (SA) node to the atrioventricular (AV) node

Corresponding author: Stephen D. Waterford.

E-mail: waterfordsd@upmc.edu

Doi: 10.5606/tgkdc.dergisi.2024.86520

Received: June 15, 2024

Accepted: June 25, 2024

Published online: July 23, 2024

Cite this article as: Waterford SD, Ad N. Surgical ablation of atrial fibrillation: Rationale and technique. Turk Gogus Kalp Dama 2024;32(3):245-252. doi: 10.5606/tgkdc.dergisi.2024.86520.

©2024 All right reserved by the Turkish Society of Cardiovascular Surgery.



This is an open access article under the terms of the Creative Commons Attribution-NonCommercial License, which permits use, distribution and reproduction in any medium, provided the original work is properly cited and is not used for commercial purposes (<http://creativecommons.org/licenses/by-nc/4.0/>).

without allowing for macro-reentrant circuits to occur. These surgical incisions in the original procedure (ablation lines in the modern era) would, however, allow for a sinus impulse to activate the myocardium of both atria.^[3] The model progressed to the maze procedure, first performed in a human patient in September 1987.^[4] Currently, the Cox maze procedure remains the most effective treatment for AF with the best long-term single procedure success rate compared to any other treatment modality particularly in patients with persistent and long-standing persistent AF.^[5]

ELECTROPHYSIOLOGICAL PRINCIPLES

The maze procedure relies upon the consistent application of all lesions to interrupt macro reentrant circuits. Completion of all lesions is, therefore, crucial and omission of a single lesion means that the procedure is no longer a maze procedure, strictly speaking. To illustrate, when Cox maze IV was first introduced, it lacked a superior connecting lesion joining the right and left superior pulmonary veins.^[6] In 2005, Cox maze IV was modified to include a superior connecting lesion, thereby forming a box lesion which completely isolated the posterior left atrium. This emulated the lesion set which was present in Cox maze I, II, and III. The five-year freedom from atrial tachyarrhythmias without antiarrhythmic medications was 66% with a superior connecting lesion and 33% without a superior connecting lesion.^[6] This demonstrates the importance of not allowing deviation from the maze procedure, if rhythm outcomes are to be optimal.

Similarly, another principle to emerge from the development of the maze procedure is the importance of the coronary sinus lesion. Indeed, the second patient to undergo a maze procedure developed atrial flutter postoperatively, and this was mapped to a failure of a cryolesion on the coronary sinus, which was successfully ablated in the catheterization laboratory. Of note, it is of utmost importance that the coronary sinus lesion and the mitral isthmus lesion of a maze procedure overlap each other, to produce a transmural lesion in this area. If not, atypical left atrial flutter can occur, often at a rate of 110 rather than the rate of 150 with typical right atrial flutter. This arises from conduction across the left atrial isthmus between the inferior pulmonary veins and the posterior mitral valve annulus.^[4] Indeed, omission of the coronary sinus lesion would lead to a 10 to 15% rate of perimitral flutter postoperatively.^[7] Despite this principle clearly elucidated decades ago, modern trials continue to omit the coronary sinus lesion from the maze procedure. Indeed, the landmark randomized-controlled trial in

New England Journal of Medicine (NEJM) in 2015 which studied the maze procedure versus pulmonary vein isolation failed to include a coronary sinus lesion in the maze procedure.^[8] This trial from the CTSNet, cited nearly 500 times, also allowed the use of unipolar radiofrequency, which we know not to be effective in producing a transmural lesion. Therefore, as Dr. Cox himself subsequently commented that this was not a trial of a maze procedure.^[7] The first principle, then, is that for surgical ablation to be effective in eliminating AF, a full maze procedure including overlapping mitral isthmus and coronary sinus lesions must be performed. In addition, the type of device used is important. The 2017 American Association for Thoracic Surgery guidelines emphasize that bipolar radiofrequency clamps and cryoablation devices have the best evidence for efficacy.^[9] The use of epicardial unipolar radiofrequency ablation is not recommended, as efficacy is questionable.

In a similar fashion, the maze procedure must include both right and left atria to be considered a true maze procedure. This is because the right and left atria are electrically continuous and, therefore, what is termed a left-sided maze procedure is not truly a maze procedure at all. Thus, we encourage surgeons to perform a maze procedure which includes both atria. If the right atrial lesions are omitted, or any modifications are applied to the left sided lesion set or the epicardial coronary sinus lesion is omitted, surgeons may erroneously conclude that surgical ablation itself is ineffective. The same applies, if the lesions are incomplete or non-transmural due to technical error or the use of certain unipolar or unidirectional devices. Undoubtedly, we know from rigorous follow-up studies with rhythm monitoring that a true maze procedure produces single procedure success rate with freedom from atrial tachyarrhythmias off Class I/III anti-arrhythmic drugs of approximately 80% at five years, regardless of the type of AF in the history of the patient.^[6] Furthermore, in countries with a high prevalence of rheumatic disease, it has been stated that the maze procedure should be omitted, as it would be ineffective in patients with rheumatic mitral valve disease. However, a review of 245 patients with either degenerative or rheumatic mitral valve disease has shown equal efficacy in the two cohorts at five years, again with rigorous rhythm monitoring.^[10] More importantly, omitting a complete box lesion set; i.e., through omission of one of the connecting lesions, was a risk factor for failure of the procedure. This body of literature demonstrates that rarely is a patient not an appropriate candidate for a concomitant

maze procedure, and further demonstrates that it is modification of the original lesion set that leads to failure. This is further supported by data showing that increasing surgeon experience predicts success of the maze procedure.^[5] With each successive ablation, the probability a patient would require catheter ablation at follow-up progressively decreases.^[5]

It is worth mentioning that preoperative duration of AF and left atrial size have been studied with respect to success of the maze procedure. We do know that duration of preoperative AF predicts greater failure of the maze procedure.^[5,6,11] We also know that increasing left atrial size predicts discharge in non-sinus rhythm, and that discharge in non-sinus rhythm predicts long-term failure of the maze procedure.^[12] At the same time, patients with an enlarged left atrium can still achieve acceptable rates of return to sinus rhythm with a maze procedure. While analyzing patients with left atrial size greater than 5.5 cm on transthoracic echocardiography within six months before surgery, return to sinus rhythm at one year was lower compared to patients with left atrial size equal to or less than 5.5 cm (86% vs. 93%), but at years, rates of sinus rhythm in the large and small left atrium groups were similar (85% and 90%).^[13] This suggests that surgical ablation remains a worthwhile procedure even in those patients with risk factors for failure.

Ultimately, the electrophysiological reason that lesions must not be omitted from the maze procedure has recently been elucidated by electrocardiographic imaging (ECGI). The ECGI involves non-invasive body-surface mapping, with the patient's chest wrapped in a multi-electrode vest which allows for recording of bi-atrial AF activation sequences. The patient's torso and cardiac geometries are acquired through computed tomography scanning while wearing the vest. Body-surface potentials are, then, recorded with 252 electrodes in the vest, and 3D reconstruction of both atria is performed and the atrial surface potentials reconstructed by the system's algorithms. Using this technology, 10 patients with long-standing persistent AF without prior ablations were mapped on two occasions with an average interval between mapping of 11 days. Electrophysiological abnormalities were noted in both atria in all 10 patients and, interestingly, the location of focal and rotor activities changed between the two mappings in all 10 patients. This demonstrates that driver location changes constantly in patients with long-standing persistent AF, and underscores the reason why the maze procedure must be kept consistent from patient to patient.^[14]

TECHNICAL ASPECTS OF A PROPER MAZE PROCEDURE

We have attempted to show above that there are commonly omitted lesions and mixed messaging that is partly related to particular ablation devices promoted by the industry. The omitted lesions consist of the following: coronary sinus lesion (particularly in redo cases where the epicardial space must be freed), inferior or superior connecting lesions, and right-sided lesions. Currently, we shift focus to discuss the proper performance of a maze procedure. There are a few pitfalls to avoid. These include pacemaker implantation, phrenic nerve injury, and coronary artery injury. We first focus on these and then discuss key technical points to maximize rhythm outcome.

MAZE PROCEDURE: AVOIDANCE OF PITFALLS

Many surgeons see a pacemaker as a complication of a maze procedure or any other types of biatrial lesions. The concern centers around the right atrial lesions of the maze procedure as a cause of pacemaker implantation. To be clear, the maze procedure, if performed appropriately, should not interfere with the function of the SA node or the AV node. There are a few aspects to discuss. First, sick sinus syndrome is quite common in patients with AF regardless of the type, and an effective surgical ablation procedure such as the maze procedure would challenge the sinus node with sick sinus syndrome, culminating in need for pacemaker implantation postoperatively. There are also patients with long-standing, persistent AF and rheumatic heart disease in whom the sinus node develops fibrosis and ceases to function appropriately. Therefore, it is of utmost importance to have information on the sinus node function prior to the procedure. The need for pacemaker implantation should not be considered a complication of the maze procedure, when performed correctly. Surgeons and referring physicians should take into account higher rates of pacemaker requirements following a maze procedure or with any surgical ablation procedures that are associated with high success rate. In a report detailing our large-scale experience with the maze procedure, multiple valve procedures was the only predictor for pacemaker implantation, probably due to higher rates of AV block directly associated with the valve procedures.^[15] Second, traction of the right atrium and placement of the lesions in areas associated with the pacemaker complex can traumatize that complex and, at the same time, the left-sided lesions can inhibit the vagal innervation of the AV node.^[16] This can have the

result of a junctional or accelerated junctional rhythm postoperatively. This is not a reflection, however, of injury to the AV node. This can be shown by placement of atrial wires after every maze procedure, and ability to capture the ventricle with atrial pacing. Furthermore, the maze procedure can lead to lower amplitude of P waves, as well as an early first-degree AV block, and this can make it difficult without an atrial electrogram to identify the P waves or the high atrial rhythm, and one can conclude the rhythm to be junctional when it is sinus.^[16] This is why atrial electrograms performed with use of an atrial pacing wire are recommended, when it appears the rhythm is junctional. The principle is that a junctional rhythm should not be seen as a complication of a maze procedure; patients can remain in a junctional rhythm or what appears to be one for weeks.

There is, however, an atrial pacemaker complex which spans not only the traditional area of the AV node, but also a broader region of the upper right atrium. Indeed, sinus rates that are faster tend to originate in the upper right atrium, and those that are slower tend to arise from the lower right atrium (Figure 1). Therefore, the atriotomy should be placed

lower down in the right atrium while performing the right-sided lesions of a maze procedure. If the incision is diagonally placed, it should go diagonally upward as it moves cephalad, not the other way around (Figure 2).

Next is the avoidance of phrenic nerve injury. The phrenic nerves develop embryologically next to the caval veins. Hence, the left phrenic nerve will be close to the ligament of Marshall, the remnant of the left superior vena cava (SVC). The right phrenic nerve will likewise run next to the SVC and inferior vena cava (IVC), and it is at risk when using cryoablation for a right-sided maze, or if the surgeon leaves the tip of the cryoprobe out of the atrium and pointing toward the pericardium when doing the box lesion set of a left-sided maze. It is critical that a gauze pad be put between the probe and the right phrenic nerve, or simply that the probe be kept well away from the pericardium where the phrenic nerve resides. It is important to also remember that cryoablation can produce permanent damage to nerve tissue. Phrenic nerve injury is a poorly tolerated complication, particularly given that cardiac surgery patients often presented with cardiopulmonary symptoms including shortness of breath, and injury to the phrenic nerve

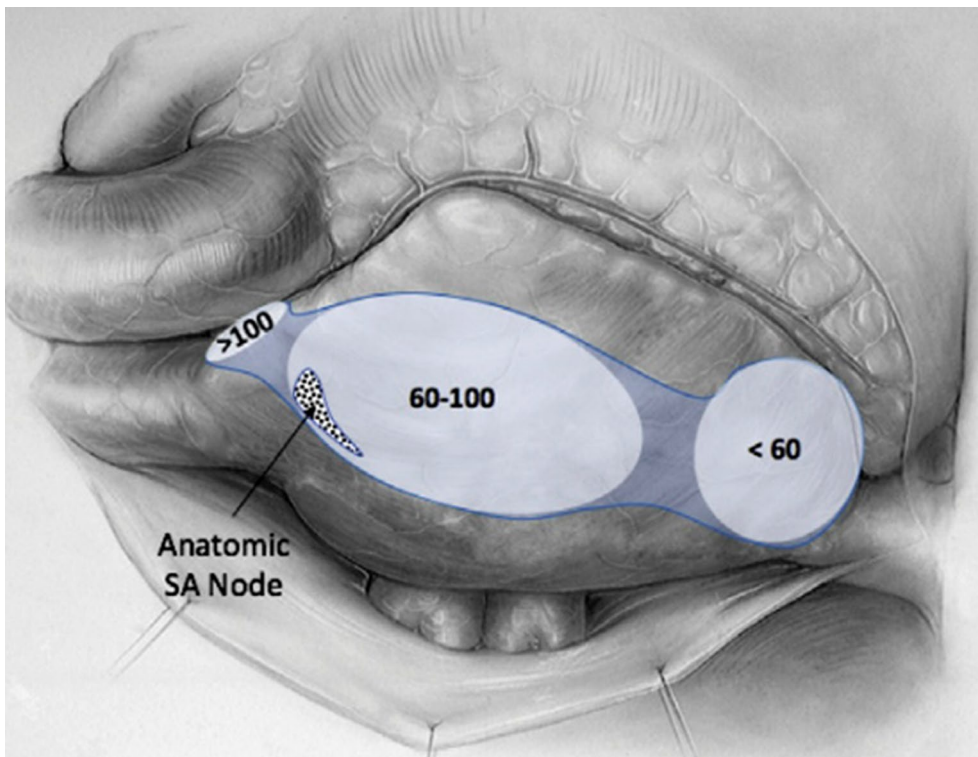


Figure 1. Atrial pacemaker complex. Faster rates arise from right atrial tissue more cephalad, and slower rates arise more caudally. Ref. No. 16.

SA: Sinoatrial.

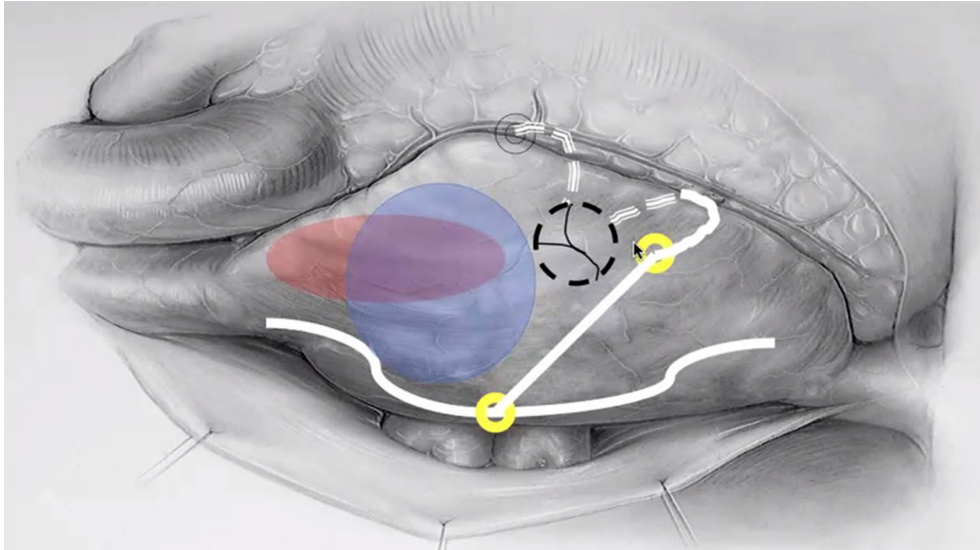


Figure 2. Proper direction of atriotomy for a right-sided lesion set. Note the incision does not cut across the atrial pacemaker complex responsible for faster rates of sinus rhythm. The yellow circles denote the sites of atriotomies during minimally invasive operations in which a full atriotomy is not performed. The black circle denotes the tricuspid valve. The white lines and grey dotted lines denote ablation lines. The red and blue regions are depictions of the atrial pacemaker complex.

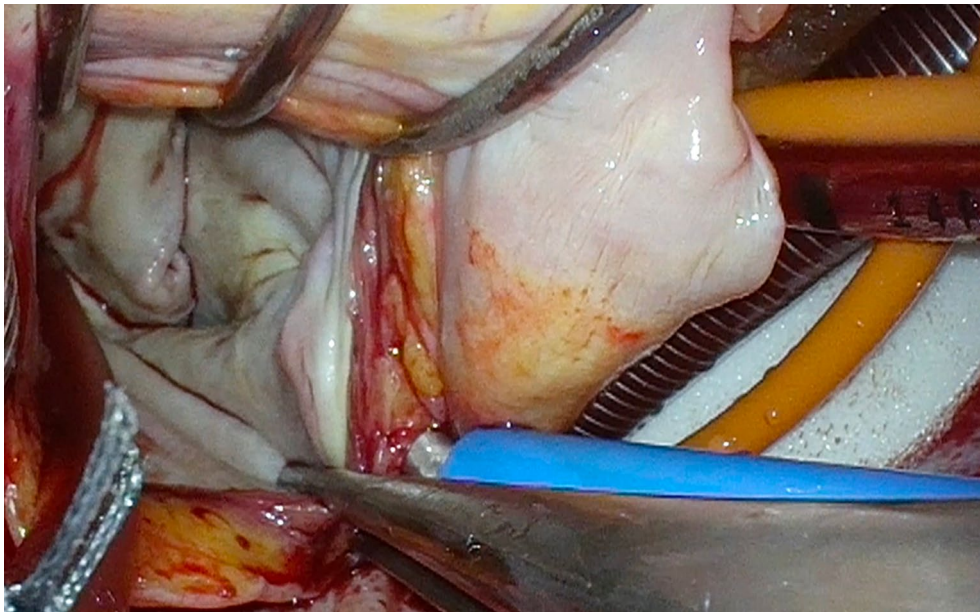


Figure 3. Protection of the phrenic nerve as it courses across the diaphragm. Note the white pad which protects the diaphragm from the cryoprobe during the coronary sinus lesion.

can lead to these symptoms persisting or worsening after surgery. Likewise, while performing the coronary sinus lesion, it is essential that the probe is not allowed to freeze the diaphragm (Figure 3).

With respect to coronary artery injury, this can only arise from the mitral isthmus and coronary sinus lesions on the left, or the 10 o'clock and 2 o'clock lesions

across the tricuspid annulus on the right. Certainly, radiofrequency clamps cannot be used to perform these lesions, as they would completely damage the coronary arteries. This is why cryoablation is required to complete a maze procedure, even if radiofrequency ablation is also used. However, it is worth being aware that Dr. Cox himself described late coronary

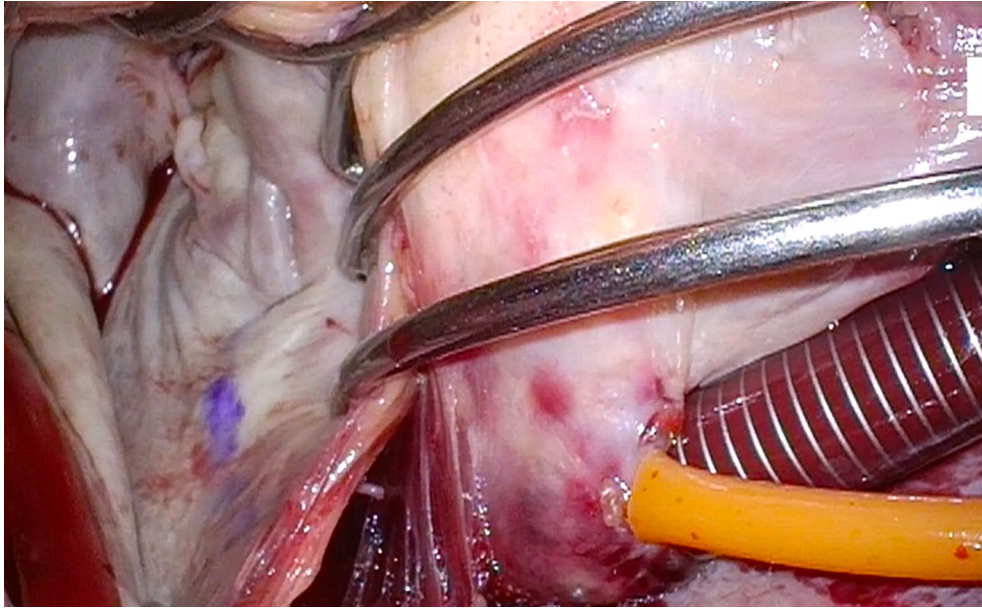


Figure 4. An image of a left atrium shows a marked lesion at the location of the coronary sinus cryolesion. The mitral isthmus lesion is, then, performed at the site of this mark.

artery neointimal hyperplasia after cryoablation was applied across coronary arteries in an animal model.^[17] This would not cause a myocardial infarction in the perioperative period, but may be responsible for a late coronary stenosis years after the maze procedure. While no formal data exist, it makes sense to perform these annular lesions with the cross-clamp off on the right side, so that blood in the right coronary artery serves as a heat sink. On the left side, one can consider running cardioplegia while performing these lesions. One series examined 20 patients who underwent cryoablation of the coronary sinus and mitral isthmus during the maze procedure.^[18] These patients had a computed tomography angiogram of the coronary arteries six months following the maze procedure, with 95% showing no coronary disease in the circumflex coronary artery and 5% (n=1) showing a 30 to 40% lesion near P1, away from the area of application of the cryoprobe near P3 on the mitral annulus. In addition, some of the anecdotal reports of coronary lesions in the literature may also be related to misplacement of the lesions.

TIPS FOR IMPROVED RHYTHM EFFICACY

The goal of a maze procedure is to produce sinus rhythm, and there are a few tips which can improve the technical efficacy of the procedure. First, if a surgeon chooses to perform a maze procedure with exclusive use

of cryoablation, as is our practice, it is recommended not to allow blood to freeze on the probe. Cell death begins to occur at -20°C (and is a combination of direct cell death and early and late apoptosis through intrinsic and extrinsic pathways), and if the probe is continuously covered with warm blood from the patient, this may inhibit apoptosis and result in an incomplete lesion. The mechanism for this effect is that blood around the probe will become frozen, and this frozen blood will create an igloo effect in which the probe itself becomes insulated from the atrial tissue. Common sites for this to occur are with pulmonary venous collateral return while performing the box lesion set, or if the right-sided lesions are done with the cross clamp off. For the left-sided lesions, placing a vent in the left pulmonary veins and also using a suction device can mitigate this issue.

With respect to coronary sinus and mitral isthmus lesions, we recommend always ensuring that the lesions are overlapping. Otherwise, a gap between the two can create atypical left atrial flutter. Figure 4 depicts an intraoperative image of a patient who has just had a coronary sinus cryolesion placed. In this lesion, a marking pen is used to mark the endocardial portion of the lesion. In this manner, the cryoprobe can be placed at this marked site to ensure that the mitral isthmus lesion is overlapping.

Finally, with respect to the SVC lesion set, we recommend performing it at 7 o'clock while looking

up the SVC through the atriotomy. This will place the lesion on the back lateral wall, away from the sinus node and atrial pacemaker complex. Placement of the probe should also take into account the location of the phrenic nerve laterally.

In conclusion, in this review, we discussed the anatomic basis for several lesions of the maze procedure and emphasized the importance of performing a complete maze procedure to ensure long-term rhythm efficacy. We also discussed avoidance of common postoperative issues such as pacemaker placement, and provided some technical points to ensure optimal placement of lesions.

It is worth also recalling that minimally invasive maze procedures have produced equivalent serious morbidity, and improved long-term rhythm outcomes, compared to more recent hybrid procedures. A systematic review has shown that on-pump right thoracotomy maze can be performed by experienced surgeons with little to no morbidity.^[19] We, therefore, recommend that as a surgical AF program develops, it incorporates right thoracotomy on-pump maze procedures as a valuable addition to the program.

Author Contributions: All authors contributed equally to the article.

Conflict of Interest: The authors declared no conflicts of interest with respect to the authorship and/or publication of this article.

Funding: The authors received no financial support for the research and/or authorship of this article.

REFERENCES

1. Lippi G, Sanchis-Gomar F, Cervellin G. Global epidemiology of atrial fibrillation: An increasing epidemic and public health challenge. *Int J Stroke* 2021;16:217-21. doi: 10.1177/1747493019897870.
2. Vervoort D, Lee G, Ghandour H, Guetter CR, Adreak N, Till BM, et al. Global cardiac surgical volume and gaps: Trends, targets, and way forward. *Ann Thorac Surg Short Reports* 2024;2:320-4. doi: 10.1016/j.atssr.2023.11.019.
3. Cox JL, Schuessler RB, Boineau JP. The development of the Maze procedure for the treatment of atrial fibrillation. *Semin Thorac Cardiovasc Surg* 2000;12:2-14. doi: 10.1016/s1043-0679(00)70010-4.
4. Cox JL. The first Maze procedure. *J Thorac Cardiovasc Surg* 2011;141:1093-7. doi: 10.1016/j.jtcvs.2010.12.012.
5. Ad N, Holmes SD, Friehling T. Minimally invasive stand-alone cox maze procedure for persistent and long-standing persistent atrial fibrillation: Perioperative safety and 5-year outcomes. *Circ Arrhythm Electrophysiol* 2017;10:e005352. doi: 10.1161/CIRCEP.117.005352.
6. Henn MC, Lancaster TS, Miller JR, Sinn LA, Schuessler RB, Moon MR, et al. Late outcomes after the Cox maze IV procedure for atrial fibrillation. *J Thorac Cardiovasc Surg* 2015;150:1168-76, 1178.e1-2. doi: 10.1016/j.jtcvs.2015.07.102.
7. Cox JL, Churyla A, Malaisrie SC, Kruse J, Pham DT, Kislitsina ON, et al. When is a maze procedure a maze procedure? *Can J Cardiol* 2018;34:1482-91. doi: 10.1016/j.cjca.2018.05.008.
8. Gillinov AM, Gelijns AC, Parides MK, DeRose JJ Jr, Moskowitz AJ, Voisine P, et al. Surgical ablation of atrial fibrillation during mitral-valve surgery. *N Engl J Med* 2015;372:1399-409. doi: 10.1056/NEJMoa1500528.
9. Ad N, Damiano RJ Jr, Badhwar V, Calkins H, La Meir M, Nitta T, et al. Expert consensus guidelines: Examining surgical ablation for atrial fibrillation. *J Thorac Cardiovasc Surg* 2017;153:1330-54.e1. doi: 10.1016/j.jtcvs.2017.02.027.
10. Labin JE, Haque N, Sinn LA, Schuessler RB, Moon MR, Maniar HS, et al. The Cox-Maze IV procedure for atrial fibrillation is equally efficacious in patients with rheumatic and degenerative mitral valve disease. *J Thorac Cardiovasc Surg* 2017;154:835-44. doi: 10.1016/j.jtcvs.2017.03.152.
11. Ad N, Holmes SD, Massimiano PS, Rongione AJ, Fornaresio LM. Long-term outcome following concomitant mitral valve surgery and Cox maze procedure for atrial fibrillation. *J Thorac Cardiovasc Surg* 2018;155:983-94. doi: 10.1016/j.jtcvs.2017.09.147.
12. Ad N, Henry L, Holmes SD, Stone LE, Hunt S. The association between early atrial arrhythmia and long-term return to sinus rhythm for patients following the Cox maze procedure for atrial fibrillation. *Eur J Cardiothorac Surg* 2013;44:295-301. doi: 10.1093/ejcts/ezs708.
13. Ad N, Henry L, Hunt S, Holmes SD. Should surgical ablation for atrial fibrillation be performed in patients with a significantly enlarged left atrium? *J Thorac Cardiovasc Surg* 2014;147:236-41. doi: 10.1016/j.jtcvs.2013.09.037.
14. Osorio-Jaramillo E, Cox JL, Klenk S, Kaider A, Angleitner P, Werner P, et al. Dynamic electrophysiological mechanism in patients with long-standing persistent atrial fibrillation. *Front Cardiovasc Med* 2022;9:953622. doi: 10.3389/fcvm.2022.953622.
15. Ad N, Holmes SD, Ali R, Pritchard G, Lamont D. A single center's experience with pacemaker implantation after the Cox maze procedure for atrial fibrillation. *J Thorac Cardiovasc Surg* 2017;154:139-46.e1. doi: 10.1016/j.jtcvs.2016.12.047.
16. Cox JL, Ad N, Churyla A, Malaisrie SC, Pham DT, Kruse J, et al. The maze procedure and postoperative pacemakers. *Ann Thorac Surg* 2018;106:1561-9. doi: 10.1016/j.athoracsur.2018.05.013.
17. Holman WL, Ikeshita M, Ungerleider RM, Smith PK, Ideker RE, Cox JL. Cryosurgery for cardiac arrhythmias: Acute and chronic effects on coronary arteries. *Am J Cardiol* 1983;51:149-55. doi: 10.1016/s0002-9149(83)80026-5.

18. Cheema FH, Pervez MB, Mehmood M, Younus MJ, Munir MB, Bisleri G, et al. Does cryomaze injure the circumflex artery?: A preliminary search for occult postprocedure stenoses. *Innovations (Phila)* 2013;8:56-66. doi: 10.1097/IMI.0b013e31828e5267.
19. Je HG, Shuman DJ, Ad N. A systematic review of minimally invasive surgical treatment for atrial fibrillation: A comparison of the Cox-Maze procedure, beating-heart epicardial ablation, and the hybrid procedure on safety and efficacy. *Eur J Cardiothorac Surg* 2015;48:531-41. doi: 10.1093/ejcts/ezu536.