

# Repair Of The Left Atrio-Ventricular Valve In Atrio-Ventricular Septal Defect

Martin Elliott MD FRCS, Mazzy Kanani FRCS

The Great Ormond Street Hospital for Children, London WC1N 3JH, UK

## Summary

The operative mortality for atrio-ventricular septal defect (AVSD) has fallen dramatically over the last 15 years as the preferred age of surgery has fallen. For the survivor, the long-term function of the left atrio ventricular valve (LAVV) is crucial in determining quality of life and to avoid re-operation. It is now well established that the zone of apposition ('cleft') between the superior and inferior bridging leaflets should be closed at initial repair. What are less well described are the other morphological features of the LAVV and the modes of repair of LAVV variations. This paper describes some of these morphological features and our concepts of the principles involved in LAVV function in AVSD. Important morphologic variants are described and suggestions given for modes of repair. The importance of the quality of LAVV repair for the patient's future is emphasised.

**Keywords:** Catheter, embolisation, venous thrombosis

Turkish J Thorac Cardiovasc Surg 2003;11:72-77

## Introduction

In the early 1980's, operative mortality for complete atrio ventricular septal defect (c-AVSD) was in the order of 25–30% in most centres. Surgery, (using either a two- or one-patch technique, was often performed after preliminary pulmonary artery banding and delayed until either the latter part of the first year of life and sometimes even later. Pulmonary hypertensive crises were a frequent cause of post-operative problems. The pioneering work of Castaneda in Boston [1,2] throughout the 1970' and 1980's led to a reduction in the preferred age of surgery to between 2-4 months of age. As that policy spread, operative mortality declined throughout the world [3], and in the UK in the year 2000 the operative mortality for c-AVSD was 1.7% in the 180 cases performed. There are relatively few data with regard to long-term mortality or left atrio ventricular valve (LAVV) function, despite the fact that many authors have described the importance of LAVV repair as part of the operation [4-6]. Although the well-established and reliable two-patch technique has many proponents [7,8], recently, the focus of attention has shifted to a primary single-patch repair as a possible preferred method of closure [9,10]. The Sidney group [9] has advocated such a method by positioning the patch entirely above the AV valve using sutures placed through the crest of the inter-ventricular septum (IVS). They report very good early results and, in doing so, challenge many of the preconceptions held about LAVV function. Reconsideration of the LAVV in AVSD is, therefore, timely.

As operative mortality approaches zero, more concentration can and must be given to improving the quality and durability of repair and the avoidance of re-operation. A key aspect of that consideration must be a deeper understanding of the LAVV and its repair. This paper considers form and function of the LAVV, and outlines some principles for assessment and repair and

indicates some gaps in knowledge which need filling. It does not consider the LAVV in functional single ventricle, in AVSD associated with tetralogy of Fallot. Or LAVV in unbalanced (L of R ventricular dominant) AVSD.

### The Morphology of the LAVV in AVSD

We have previously described the basic morphology of the LAVV in relation to repair [11], and more detailed morphological description is available in works from Anderson's group [12,13]. A key element of that morphology is the presence of the common atrioventricular junction resulting from incomplete development of the septal tissue surrounding the atrio-ventricular (AV) valves. This AV valve apparatus has been described as having either five or six leaflets surrounding the mouth of the common AV junction (Figure 1). On the left side, the leaflets have been termed left superior, left lateral (mural), and left inferior. On the right side, the leaflets have been similarly termed, but with the prefix 'right'. The point at which the superior and inferior bridging leaflets come into proximity has been termed the "zone of apposition", and this represents an important surgical landmark.

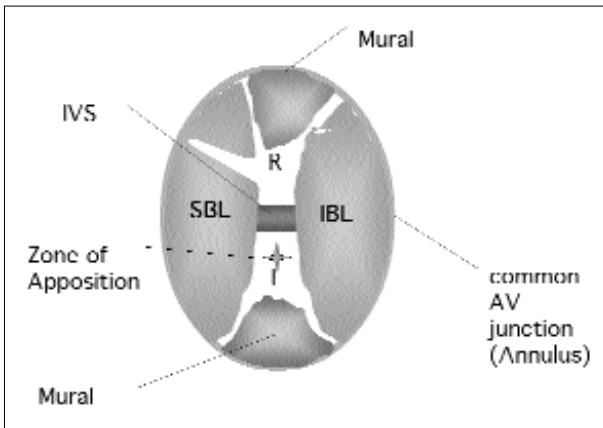
In the complete AVSD, a five-leaflet model is the usual form with prominent superior and inferior bridging leaflets. These exhibit some variation in both the amount of leaflet tissue that straddles the inter-ventricular septum, and the degree of chordal attachments to it. It is this degree of bridging and chordal attachment that forms the basis of the Rastelli classification of complete AVSD originally described in 1966 [14].

Unfortunately, not all patients follow the predictable pattern and there is wide individual variation. It is the understanding of that variation and the resolution of that variation into principles of repair that is the concern of this paper. We will consider in more detail variation in leaflet shape and number; relative size

**Sunulduđu Kongre:** Türk Kalp Damar Cerrahisi Derneđi VII. Ulusal Kongresi, 23-27 Ekim 2002, Antalya

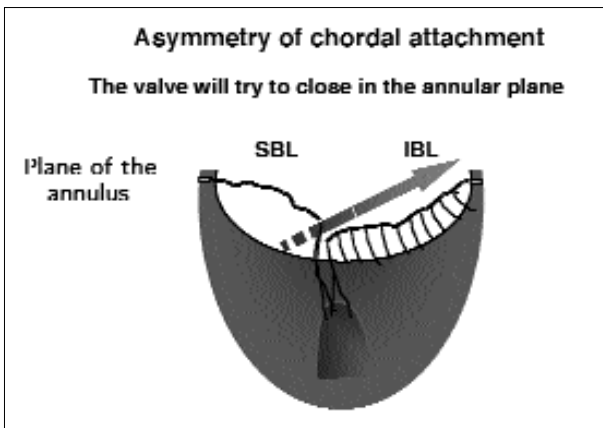
**Adres:** Martin Elliott MD FRCS, Chief of Cardiothoracic Surgery, The Great Ormond Street Hospital for Children, London WC1N 3JH, UK

**e-mail:** elliom1@gosh.nhs.uk



**Figure 1.** This figure shows the most frequent arrangement of AV valve tissue in cAVSD.

IVS = inter-ventricular septum  
SBL & IBL = superior and inferior bridging leaflets

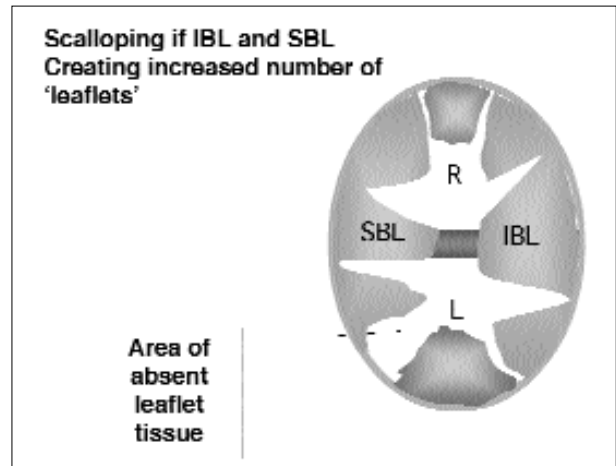


**Figure 3.** This figure demonstrates the role of asymmetric secondary chordal attachment in a Rastelli type C cAVSD. The differential tethering can cause significant regurgitation in addition to regurgitation via the “cleft”.

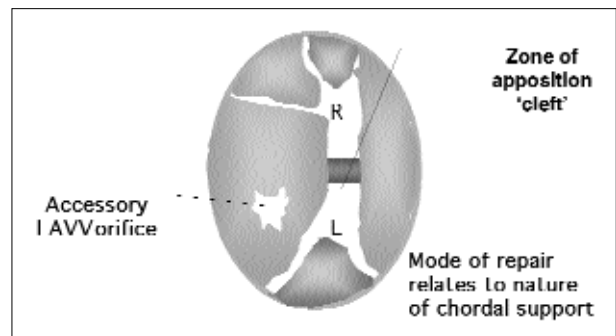
of leaflets, especially the left mural leaflet; primary and secondary chordal attachment; role of accessory orifices; absence of tissue; and relationship of valvar tissue to the annular plane of the common AV orifice.

#### Leaflet Shape and Number

Figure 1 shows the most common arrangement of common AV valve leaflet tissue in AVSD. However, valve tissue is not always uniformly distributed, and scalloping of either the superior (SBL) or inferior (IBL) bridging leaflets can create a larger number of ‘leaflets’ (Figure 2). Whilst they clearly represent SBL or IBL leaflet tissue, in practice they function as separate leaflets, and the orientation of those leaflets can influence the mode of repair. If the scalloping between leaflets overlies the septum, repair can become complicated. The surgeon will have to decide whether to close stitch the leaflets together or to leave the inter-leaflet commissure alone.



**Figure 2.** This figure shows extensive scalloping of the superior and inferior bridging leaflets. Note how this creates the impression of a large number of leaflets. Their significance relates to the relationship to the IVS and areas of deficiency.




**Figure 4.** This figure shows an accessory leaflet in the SBL and a nearby zone of apposition “cleft”. It is clear that such differentiation may be difficult in real life.

#### Leaflet Size

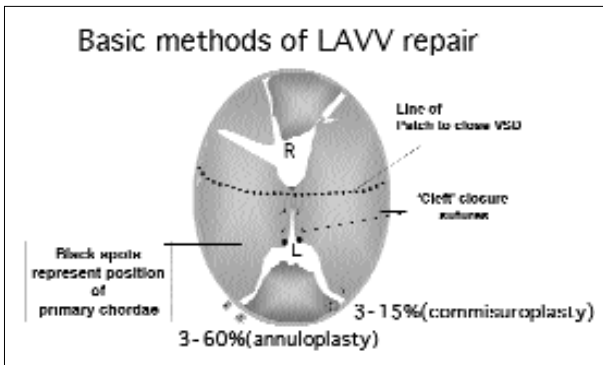
Each of the main leaflets in AVSD can vary in size. However, the dimensions of the left mural leaflet are the most important. As we will describe below, closure of the zone of apposition (“cleft”) is critical to long-term LAVV function. If the “cleft” is closed in the presence of a diminutive L mural leaflet, then it can be very easy to create effective LAVV stenosis. Fear of this often results in relatively conservative “cleft” repair, and thus a higher incidence of post-operative LAVV regurgitation occurs in this setting. Ebels’ group has studied the L mural leaflet extensively and have reported the importance of the echocardiographic inter-papillary muscle distance and their radial distribution.

#### Primary and Secondary Chordal Attachment

In this paper, primary chords are described as those attached to the free margin of the valvar leaflets, and secondary chords as those attached to the underside of the AV valve leaflets. We are not differentiating between 2nd and 3rd level chords in this report since, currently, we are unaware of the true significance



**Figure 5.** The plane of the annulus is defined as the plane drawn through the level of the junction between the atria and ventricles. It represents the plane of the atrio-ventricular junction. The valve is designed to close in this plane.




**Figure 7.** This diagram shows the most common basic principles of LAVV repair in cAVSD. The “cleft” should always be closed. The stated incidences of annuloplasty and commisuroplasty show the ranges reported in the literature.

of these divisions This question is presently the subject of investigation, with the hope of being more specific about chordal arrangements in up-coming reviews. The chordal attachments from the underside of the SBL and IBL are the most important because they influence the plane of valve closure, the severity of any regurgitation and can limit inter-ventricular shunting (Figure 3).

In classic Rastelli-type C AVSD, the superior bridging leaflet is free floating, and there is no secondary chordal attachment to the IVS. Yet, even in Rastelli-type C, there may be significant secondary chordal attachment of the IBL to the IVS.

**Accessory Orifices**

Accessory orifices Figure 4 can be found in any relatively large leaflet, but are most often seen in either the S or IBL on the left side. They can be very difficult to identify, and equally difficult to assess. One must identify the chordal attachments to the free margin and be careful to differentiate such an orifice from a “cleft” or partial “cleft”.



**Figure 6.** This figure shows the importance of the relationship of the plane of closure to shunting through the base of the “cleft” in partial AVSD. There is no true VSD beneath either the SBL or IBL, but because the leaflets close in the plane of the annulus, shunting can occur through the ‘cleft’ below the competent AV leaflets.

**Absence of Tissue**

Leaflet tissue may be absent in area of the valve tissue guarding the AV junction. The less valve tissue there is, the harder the repair. Occasionally, one may encounter almost complete absence of AV valve tissue, under which circumstances a child will present with gross AV valve regurgitation immediately after birth, and repair may be impossible.

**Relationship to the Plane of the Annulus of the AV Junction**

The concept of the plane of the annulus at the level of the AV junction is important in considering the physiology of common AV valve closure in cAVSD.

This relationship is shown in (Figure 5). The superior and inferior bridging leaflets should rest at this level during systole if the sub-valvar support system is normal. Often, as described above, secondary chordal attachments may hold down the leaflets to the crest of the inter-ventricular septum, increasing the potential for regurgitation.

**Physiological Function of the AV Valve in cAVSD**

As described above, and as shown in the figures, the common AV-valve will always try to close in the plane of the annulus. This is an important principle to understand and is the basis of two-patch repair of AVSD and of the one-patch repair used by followers of the Boston group. It is not absolutely necessary for a common AV valve to close in the plane of the annulus in order to be competent, but it is a distinct advantage, especially if there is asymmetry of the chordal attachment (Figure 3). Restoration of symmetry is critical to successful repair,

whichever method is used. In the absence of significant secondary chordal attachment, it is the primary chords which hold the margins of the AV valve in the correct position and maintenance of the position and integrity of these chords is very important to ensure post-operative competence.

The concept of closure at the plane of the annulus may also be used to explain those cases of partial AVSD in which the base of the "cleft" can function as a pseudo-ventricular septal defect, creating either inter-ventricular shunting or ventriculo-atrial shunting.

In partial AVSD, in which there are effectively partitioned AV orifices, the AV valves can close completely competently in the plane of the annulus. However, because they may be concomitant scalloping of the true inter-ventricular septum, with the partition between ventricles being formed by sub-valvar tissue or fused secondary chordae, any "cleft" in the LAVV may fold down a proportion of its length, leaving part of the "cleft" below the plane of the annulus. This creates the substrate for a VSD as shown in Figure 6. This concept can be used to adapt repair in many hearts.

### **Principles and Methods of LAVV Repair**

For simplicity, this discussion assumes that a two-patch repair of AVSD is the method chosen (for a more detailed review of the two-patch repair see Elliott & Jacobs, 1999). The basic principles would also apply to a Boston-style single patch. The implications for the single patch repair proposed by the Sidney group [9], which challenge some of the assumptions we make, are discussed below.

We believe that, wherever possible, the AV valves should be repaired such that they close in the plane of the annulus. This is the natural plane of closure and should in theory provide a more stable structure to guarantee competence. If this concept is to be followed, certain steps will need to be taken in the early part of the operation. Firstly, unless the sub-valvar apparatus is fused so as to create a functional partial AVSD, tethering secondary chords attaching the bridging leaflets must be divided. To facilitate this we have described elsewhere [11] the technique of placing stay-sutures at the kissing points of the bridging leaflets. Once these sutures are in place, careful retraction is facilitated and differentiation of secondary chordae from primary chordae becomes easier and chordal division safer. The division of secondary chordae over the inter-ventricular septum can continue until it is clear that the bridging leaflets will float up to the plane of the annulus. Because an inter-ventricular patch is to be inserted below the leaflet tissue, one can be a little more aggressive in chordal division since the patch will prevent prolapse of the repaired valve. Once confident that the leaflets are adequately mobilised, the inter-ventricular patch can be cut to size, usually in a crescent-shape. The height of this patch should reflect the distance between the crest of the inter-ventricular septum and the plane of the annulus.

### **Closure of the Zone of Apposition**

We always close the zone of apposition on the left side of the inter-ventricular septum, as shown in (Figure 7). There is usually reasonably strong tissue at the margins of the "cleft", but we always reinforce the closure with autologous pericardial pledgets. In infants, 6:0 8mm Prolene horizontal mattress sutures are very effective. It is important to have some idea of how much of the "cleft" needs closing. We have found it useful

to identify the left-sided primary chords on each bridging leaflet, and to use sufficient sutures (usually two) to close the "cleft" between the marked kissing points at the base of the "cleft" and the first primary chord on each bridging leaflet. Sometimes, the primary chords on the SBL and IBL are found at different distances from the kissing points. Asymmetric placement of the horizontal mattress sutures can compensate for this, and create a well-balanced arrangement of the AV valve tissue. We have not found it helpful to test the valve until after the atrial patch has been placed and the "cleft" has been closed; to test it earlier is of little value since placement of the atrial patch can alter the annular dimensions. The valve is tested using ice-cold saline delivered via a small naso-gastric tube attached to a 50ml syringe. The cardioplegia cannula in the aortic root must be disconnected to allow a vent site for any air inadvertently introduced to the left ventricle. Careful review of the valve at this stage will expose the need for any additional procedures to the LAVV.

The literature reflects significant institutional variation with regard to the procedures used on the LAVV additional to 'cleft' closure. For example, the incidence of annuloplasty sutures being needed in repair ranges from 3% to 60% [6,15,16], and for commissuroplasty from 3 to 15% [17]. It seems highly unlikely that 60% of AV valves actually need an annuloplasty, so this must reflect that surgeon's personal preference. It is important to understand this; otherwise it can be very difficult to interpret the literature. It seems to us more important to attempt to understand the individual valve and repair it in the manner it needs, rather than state that a particular procedure is always required. The only exception to this rule is 'cleft' closure, which must be done (see results below).

Annuloplasty is usually done by placing horizontal mattress, pledgetted, sutures in the atrial tissue at the position of a commissure over a varying distance of the annulus. Commissuroplasty is best suited to localized lack of tissue at a commissure, and involves approximation of the leaflets at the commissure with sutures placed in valve tissue only. The two techniques can be combined by placing one arm of the suture through valve tissue and one through annular tissue.

### **Management of the Small Mural Leaflet**

A small mural leaflet can seriously complicate repair. It may not be possible completely to close the 'cleft' to the primary chordae without causing effective LAVV stenosis. Certainly, the LAVV valve should be measured with Hegar dilators to assess size against the expected size for a mitral valve, and the valve must be tested for competence. The smaller the mural leaflet, the more difficult the compromise. If a small mural leaflet is identified either pre- or per-operatively, the family of the patient must be warned that the prognosis for the LAVV is poor. Ebels' group have described the use of a 'protractor' specifically to determine the importance of mural leaflet size. They use the protractor to inform decision making in the operating room. We have not found the use of such a device to be helpful or necessary, but are reviewing that assessment as part of our current research.

### **Management of Accessory Orifices**

As we have stated above, accessory orifices in the LAVV can be difficult to identify, as they can easily be confused with the 'cleft' in the small heart. Such differentiation is very important,

however, since the accessory orifice may contribute a significant proportion of the inflow to the left ventricle. The surgeon must determine whether the orifice has chordal attachment to its free margins, and determine whether the orifice is competent. It should not be closed unless these are not present. Accessory orifices without chordal support are rare, but when they are they can cause significant regurgitation and should be closed. Unfortunately, this closure may require a small patch to avoid distortion of the AV valve.

#### **Management of LAVV Valve with Deficient Tissue**

Deficiency of tissue can be very difficult to resolve. It is more common in our experience in those patients without trisomy 21. The less tissue there is, the worse the outcome. The basic principle of most repairs is to plicate either or both the valve tissue on either side of the deficiency, or the annulus. The 'cleft' should usually still be closed. However, it is obvious that the more plication is required, the less AV orifice there is and thus the less the effective orifice area. The surgeon may have to leave the 'cleft' open to allow enough inflow to the LV and obviously this will increase the risk of important residual AV valve regurgitation. In theory, a leaflet can be extended with an autologous pericardial patch, but we have only been able to achieve this in one case with only moderate effect. In patients with important deficiency, perfection should not be sought. Much better to improve LAVV function just enough to allow the child to survive surgery and grow such that, at a later operation, further valve repair or replacement may be possible. If there simply is not enough tissue to achieve any kind of repair, valve replacement may be necessary. This too can be a very difficult operation in the small baby [18]. The valve (the smallest is a size 16mm Carbomedics valve) will usually have to be placed in the supra-annular position, which in itself is not easy when the medial component is made up of the inter-atrial patch of the AVSD repair. The coronary sinus may also be on the left side and, in avoiding sub-valvar placement of the sinus, the conduction system can easily be damaged. If the absence of valve leaflet tissue is close to the inter-ventricular septum or the new VSD patch, it may not be necessary to do anything about. The final position of the inter-atrial and inter-ventricular patches may be such that the valve tissue may balloon up during systole and close up against the patches without the need for sutures and with effective competence. Occasionally, attachment of the free margin of a leaflet to the upper part of the VSD patch will also be necessary.

#### **Importance of Intra-Operative Echocardiography**

Echocardiography, either epicardial or trans-oesophageal, is extremely good at identifying residual defects and assessing AV valve function after cAVSD repair. In our view, and that of others [19,20], all repairs should be checked by echocardiography before leaving the operating room. The best possible result must be obtained, and it is almost always easier to sort out at the first operation than a few days later when the child is sick in the intensive care unit. We have observed in our own practice over the years that LAVVR observed at the end of surgery rarely gets better and usually gets worse, hence our current practice of sorting it out at the time.

#### **Simplified Single Patch Repair**

In 1999, Nicholson et al from Sidney reported [9] a simplified

single patch repair of cAVSD. In this repair, the common AV valve is fixed down to the scalloped inter-ventricular septum by a single patch. Early results are indistinguishable from other recent series, and thus challenge all the arguments given above supporting the plane of the annulus as the key factor in achieving successful long-term repair of LAVV in AVSD. Along with others, we have concerns about the left ventricular outflow tract in this repair, and we are uncertain how effective the repair can be in cases of complex anatomy such as those described above. More long-term data are needed, and ideally from other centres. We are very interested in any technique which reproducibly simplifies surgery. If good results are sustained there may well be an indication for a prospective randomised trial.

## **Results**

We have already discussed the dramatic improvement in operative mortality results for cAVSD in recent years. Of more importance to this paper are the incidences of LAVV regurgitation and re-operation. Table 1 demonstrates summary data from recent publications relating to these indices. A number of inferences may be drawn from these data.

1. The zone of apposition should always be closed.
2. LAVVR occurs most frequently early after repair and only rarely occurs later.
3. There is a persistent re-operation rate in all series. Thus there is still considerable room for improvement.
4. There are rarely enough data fully to explain which valves are most likely to require re-operation.
5. On the whole, the earlier the AV valve is repaired, the less long term LAVVR there is.

## **Discussion**

Complete AVSD can be repaired with low mortality in the current era. There remains a persistent re-operation rate, largely related to LAVV regurgitation. This re-operation rate must be reduced. We know that the zone of apposition must be closed to minimise re-operation rate and maximise survival, but there are no available data on other aspects of LAVV morphology in relation to outcome and re-operation rate. We believe that the LAVV in cAVSD should be described according to the principles we describe in this paper. There is much more research to be done, and a more accurate morphologic classification may inform repair and improve long-term re-operation rates.

## **References**

1. Hanley FL, Fenton KN, Jonas RA, et al. Surgical repair of complete atrioventricular canal defects in infancy. Twenty-year trends. *J Thorac Cardiovasc Surg* 1993;106:387-94.
2. Chin AJ, Keane JF, Norwood WI, Castaneda AR. Repair of complete common atrioventricular canal in infancy. *J Thorac Cardiovasc Surg* 1982;85:437-45.
3. Weintraub RG, Brawn WJ, Venables AW, Mee RB. Two-patch repair of complete atrioventricular septal defect in the first year of life. Results and sequential assessment of atrioventricular valve function. *J Thorac Cardiovasc Surg* 1990;99:320-6.

4. Wetter J, Sinzobahamvya N, Blaszczyk C, et al. Closure of the zone of apposition at correction of complete atrioventricular septal defect improves outcome. *Eur J Cardio Thorac Surg* 2000;17:146-53.
5. Suzuki K, Tatsuno K, Kikuchi T, Mimori S. Predisposing factors of valve regurgitation in complete atrioventricular septal defect. *J Am Coll Cardiol* 1998;32:1449-53.
6. Capouya ER, Laks H, Drinkwater DC Jr, Pearl JM, Milgalter E. Management of the left atrioventricular valve in the repair of atrioventricular septal defects. *J Thorac Cardiovasc Surg* 1992;104:196-201.
7. Bogers AJJC, Akkersdijk GP, de Jong PL, et al. Results of primary two-patch repair of complete atrioventricular septal defect. *Eur J Cardiothorac Surg* 2000;18:473-9.
8. Backer CL, Mavroudis C, Alboliras ET, Zales VR. Repair of complete atrioventricular canal defects: Results with the two-patch technique. *Ann Thorac Surg* 1995;60:530-7.
9. Nicholson IA, Nunn GR, Sholler GF, et al. Simplified single patch technique for the repair of atrioventricular septal defect. *J Thorac Cardiovasc Surg* 1999;118:642-6.
10. Prifti E, Bonacchi M, Leacche M, Vanini V. A modified 'Single Patch' technique for complete atrioventricular septal defect correction. *Eur J Cardiothorac Surg* 2002;22:151-3.
11. Elliott MJ, Jacobs JP. Atrioventricular canal defects. In Kaiser LR, Kron IL, Spray TL, eds. *Mastery of Cardiothoracic Surgery*. Lippincott-Raven Publishers: Philadelphia, 1998:742-58.
12. Anderson RH, Ho SY, Falcao S, Daliento L, Rigby ML. The diagnostic features of atrioventricular septal defect with common atrioventricular junction. *Cardiol Young* 1998;8:33-49.
13. Anderson RH, Zuberbuhler JR, Penkoske PA, Neches WH. Of clefts, commissures, and things. *J Thorac Cardiovasc Surg* 1985;90:605-10.
14. Rastelli G, Kirklin JW, Titus JL. Anatomic observations on complete form of persistent common atrioventricular canal with special reference to atrioventricular valves. *Mayo Clinic Proc* 1966;41:296-308.
15. Reddy VM, McElhinney DB, Brook MM, Parry AJ, Hanley FL. Atrioventricular valve function after single patch repair of complete atrioventricular septal defect in infancy: How early should repair be attempted? *J Thorac Cardiovasc Surg* 1998;115:1032-40.
16. Miyamura H, Eguchi S, Watanabe H, et al. Total circular annuloplasty with absorbable suture for the repair of left atrioventricular valve regurgitation in atrioventricular septal defect. *J Thorac Cardiovasc Surg* 1994;107:1428-31.
17. Tlaskal T, Hucin B, Marek J, et al. Individualised repair of the left atrioventricular valve in spectrum of atrioventricular septal defect. *J Cardiovasc Surg* 1997;38:233-9.
18. Ando M, Fraser CD Jr. Prosthetic mitral valve replacement after atrioventricular septal defect repair: A technique for small children. *Ann Thorac Surg* 2000;72:907-9.
19. Lee HR, Montenegro LM, Nicolson SC, Gaynor JW, Spray TL, Rychik J. Usefulness of intraoperative transoesophageal echocardiography in predicting the degree of mitral regurgitation secondary to atrioventricular defect in children. *Am J Cardiol* 1999;83:750-3.
20. Canter CE, Sekarski DC, Martin TC, Guitierrez FR, Spray TL. Intraoperative evaluation of atrioventricular septal defect repair by color flow mapping echocardiography. *Ann Thorac Surg* 1989;48:544-50.
21. Bando K, Turrentine MW, Sun K, et al. Surgical management of complete atrioventricular septal defects. A twenty year experience. *J Thorac Cardiovasc Surg* 1995;110:1543-52.
22. Najm HK, Coles JG, Endo M, et al. Complete atrioventricular septal defects: Results of repair, risk factors, and freedom from reoperation. *Circulation* 1997;96:311-5.
23. Crawford FA Jr, Stroud MR. Surgical repair of complete atrioventricular septal defect. *Ann Thorac Surg* 2000;72:1621-8.
24. Boening A, Scheewe J, Heine K, et al. Long-Term results after surgical correction of atrioventricular septal defects. *Eur J Cardiothorac Surg* 2002;22:167-73.