

Aort Cerrahisinde Nadir Bir Komplikasyon: Sağ Ventrikül Çıkım Yoluna Rüptüre Mediastinal Psödoanevrizma Olgusu

RUPTURED PSEUDOANEURYSM INTO THE RIGHT VENTRICLE OUTFLOW TRACT AFTER ASCENDING AORTA REPLACEMENT

Murat İkizler, *Bahadır Gültekin, *Atilla Sezgin, *Atılay Taşdelen

Osmangazi Üniversitesi Tıp Fakültesi, Kalp Damar Cerrahisi Ana Bilim Dalı, Eskişehir
*Başkent Üniversitesi Tıp Fakültesi, Kalp Damar Cerrahisi Kliniği, Ankara

Özet

Mediastinal psödoanevrizma kalp ve aort cerrahisi sonrasında beklenen komplikasyonlar arasında olmasına karşın, yaygın görülen bası semptomlarının yanında komşu dokulara rüptüre olması nadir olarak izlenmektedir. Bu raporda 55 yaşında bir bayan hastada saptanan ve sağ ventrikül çıkım yoluna rüptüre olmuş bir mediastinal psödoanevrizma olgusu sunulmaktadır. Psödoanevrizma, çıkan aort replasmanı sonrasında anastomoz hattında oluşan sütür yetersizliğine bağlı olarak oluşmuş ve sağ ventrikül çıkım yolunda pulmoner kapağın hemen altına rüptüre olmuştur. Hasta ikinci kez opere edilerek psödoanevrizma çıkartılmış ve rüptür bölgesi ile anastomoz hattı başarı ile tamir edilmiştir.

Anahtar kelimeler: Mediastinal psödoanevrizma, rüptür, aort, greft

Türk Göğüs Kalp Damar Cer Derg 2004;12:271-273

Summary

Mediastinal pseudoaneurysm is a rare complication of cardiac and aortic surgery. We report a 55-year-old woman with mediastinal pseudoaneurysm ruptured into the right ventricle outflow tract. The pseudoaneurysm developed after the ascending aort replacement due to suture line dehiscence and it was re-operated successfully with no need to replace the graft. This case illustrates that mediastinal pseudoaneurysm is a potential complication after aortic surgery and it has the ability of rupture into the neighboring structures.

Keywords: Mediastinal pseudoaneurysm, rupture, aort, graft

Türk Göğüs Kalp Damar Cer Derg 2004;12:271-273

Introduction

Mediastinal pseudoaneurysm is a rare but potentially fatal complication of cardiac surgery. The problem usually occurs after the ascending aorta or aort-coronary bypass surgery, and predisposing factors include suture line dehiscence due to infection at the anastomosis site, degenerative aortic diseases, and aortic dissections [1]. In addition to these factors, Katsumata and colleagues [2] have reported that excessive use of formalin in gelatin-resorcin-formol glue might cause tissue necrosis at the anastomosis site, and thus lead to late dehiscence. In this case, we used tissue glue as a thin layer for both suture lines.

Case Report

A 55-year-old hypertensive female was admitted to hospital with the symptoms of palpitation, chest pain, and fatigue, and physical examinations revealed dilatation of the ascending aorta (6.4 cm). The dilatation was involving in inferior wall of the arcus aorta. The major branches of the aortic arch were observed in normal diameter. Since there was no coronary

artery occlusion or aortic valve insufficiency, the patient underwent supracoronary ascending aorta replacement with a dacron graft via median sternotomy. Both proximal and distal suture line were covered with tissue glue. The postoperative course was uneventful. The patient was discharged from hospital on day 8th post-surgery, and was prescribed with antiagregant therapy.

After three months from operation, she returned for routine follow-up examinations. She was complaining of paroxysmal nocturnal dyspnea and pedal edema. The physical examination of patient revealed a continuous murmur located in the second intercostal space at the left side of sternum. Her chest x-ray and echocardiogram revealed widening of the upper mediastinum by an unidentified mass, so computed tomography and angiography were also performed. These methods confirmed that there was a pseudoaneurysm on the posterior side of the ascending aorta, and furthermore the pulmonary artery became visible after visualization of the pseudoaneurysm was appeared during aortography (Figure 1).

Surgical treatment was necessary, so the patient was operated after three months of her initial procedure. A pseudoaneurysm was located in the anterior mediastinum. The dimensions of the sac were 15x20 cm. It was arising from the posterior side of the

Adres: Dr. Murat İkizler, Osmangazi Üniversitesi Tıp Fakültesi, Kalp Damar Cerrahisi Ana Bilim Dalı, Eskişehir
e-mail: mikizler@ogu.edu.tr

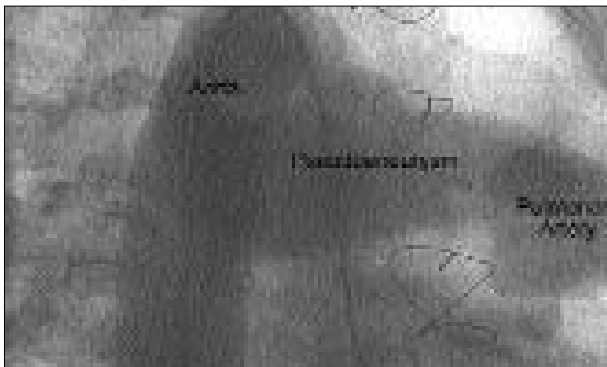

Figure 1. The aortography of the patient before her second operation. The Catheter is in the left ventricle. The pseudoaneurysm and pulmonary artery became visible after opaque injection.

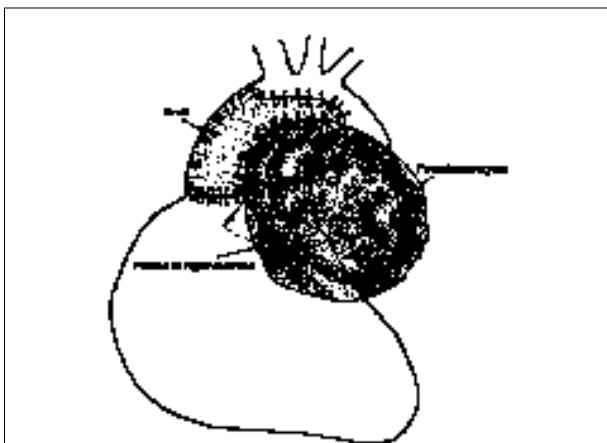


Figure 2. The schematic view of the pseudoaneurysm. Its origin was at the posterior side of ascending aorta and was extending on to pulmonary artery.

ascending aorta and was extending to the pulmonary artery (Figure 2). The right atrium was cannulated, and deep systemic hypothermia was induced via the femoral artery cannulation. Total circulatory arrest was then induced. When the pseudoaneurysm was opened and resected, we discovered that it had ruptured into the right ventricle outflow tract. The origin of the hemorrhage was clearly visible on the posterior side of the aortic dacron graft, where blood was escaping due to suture line dehiscence at the distal anastomosis. We were able to repair the suture line, and there was no need to replace the graft. The dehiscence of the suture line was repaired from inside of the graft using interrupted teflon-supported 3/0 monofilament sutures. Then the gap on the graft was closed with 3/0 monofilament sutures. The defect in the right ventricle outflow tract was repaired using teflon felts and continuous 3/0 monofilament sutures. There was no complication during the operation or in the postoperative course, and she was discharged 8 days after her second surgery.

After two months, the patient returned for a routine check-up. Radiographic examinations and echocardiography revealed no abnormal findings. She was asymptomatic, well, and engaging in normal daily activities.

Discussion

In our patient, the abnormality was suspected based on radiographic and echocardiographic findings. Computed tomography and angiography confirmed that it was a pseudoaneurysm. We did not perform other imaging techniques, because these methods had provided a definite diagnosis. Electron-beam tomography [3] and magnetic resonance imaging [4] are other techniques that can be used for diagnosis and postoperative follow-up of pseudoaneurysms. These are expensive but useful, and are most often used to investigate pseudoaneurysms, which arise from aorta-coronary bypass grafts.

The aortic pseudoaneurysm may progressively broaden and compress other mediastinal organs. Cerebral or peripheral embolism can also occur originating from a thrombus in the pseudoaneurysm. Neither compression nor embolism complications occurred in our patient. In some circumstances, a false aneurysm may rupture into a cavity or into neighboring organs. Güler and associates [8] have reported the relationship between aortic pseudoaneurysm and aorto-bronchial fistula after coarctation repair. Likewise several reports have been described the ruptured aortic pseudoaneurysms into the pericardium [9]. In our case, the pseudoaneurysm ruptured into the right ventricle outflow tract as reported in literature.

Surgery is mandatory for complicated or large pseudoaneurysms. A repeated sternotomy approach may cause the sac to rupture with major bleeding; thus, it is recommended that femoral arterial anastomosis should be done prior to sternotomy in these cases. We also administered full-dose heparin and placed a femoral artery cannula for safety before dissecting the false aneurysm. The site of rupture was on the posterior side of the dacron graft, and it was not possible to make the repair in that position. Deep hypothermia and total circulatory arrest were induced and the anastomotic leak was repaired safely and with a good visualization. Coselli and colleagues [7] advocated that aortic prostheses should not be replaced, even in mediastinitis, if the infection is sensitive to antibiotics. In our patient, since there was no infection in the graft, and the surrounding tissue and the native aortic wall were normal, the graft did not need to be replaced.

Mediastinal pseudoaneurysm is a serious problem that can cause a number of life-threatening complications, such as cerebral embolism or major bleeding due to aneurysm rupture. Fistulation or rupture of a pseudoaneurysm into neighboring tissues and cavities is rare but it may occur. We strongly recommend that all mediastinal false aneurysms should be comprehensively evaluated. This is the only way that the surgeon can properly plan the procedure and avoid any unexpected difficulties.

References

1. Sullivan KL, Steiner RM, Smullens SN, Griska L, Meister SG. Pseudoaneurysm of the ascending aorta following cardiac surgery. *Chest* 1988;93:38-43.
2. Katsumata T, Moorjani N, Vaccari G, Westaby S. Mediastinal false aneurysm after thoracic aortic surgery. *Ann Thorac Surg* 2000;70:547-52.
3. Gulbins H, Becker C, Kilian E, Reichenspurner H, Reichart B. Pseudoaneurysms after Bentall's procedure in acute

- aortic dissection type A: Diagnosis using electron beam tomography. *Z Kardiol* 2000;89:195-8.
4. Dagenais F, Cartier R, Paquet E, Hudon G, Castonguay Y, Leclerc Y. Pseudoaneurysm after Bentall repair: magnetic resonance imaging assessment. *Can J Cardiol* 1993;9:869-72.
 5. Güler M, Keleş C, Eren E, Erşahin S, Yakut C. Late development of aortic pseudoaneurysm and aorto bronchial fistula after coarctation repair with patchplasty. *Türk Göğüs Kalp Damar Cer Derg* 2001;9:54-6.
 6. Nonaka K, Makuuchi H, Naruse Y, Kobayashi T, Goto M, Yamamoto T. Pseudoaneurysm of the aortic arch and ruptured into the pericardium - a case report of successful surgical management. *Jpn J Thorac Cardiovasc Surg* 1998;46:772-6.
 7. Coselli JS, Crawford ES, Williams TW Jr, et al. Treatment of postoperative infection of the ascending aorta and transverse aortic arch, including use of viable omentum and muscle flaps. *Ann Thorac Surg* 1990;50:868-81.