

Aortik Balon Valvüloplastiye Bağlı Mitral Kapak Hasarı Ve Cerrahi Tedavisi

MITRAL VALVE INJURY DURING AORTIC BALLOON VALVULOPLASTY AND ITS SURGICAL TREATMENT

Ece Salihoğlu, Ersin Ereğ, Yusuf Kenan Yalçınbaş, *Nilüfer Öztürk, **Ayşe Sarıoğlu, Tayyar Sarıoğlu

İstanbul Memorial Hastanesi, Kalp Damar Cerrahisi Kliniği, İstanbul
**İstanbul Memorial Hastanesi, Pediatrik Yoğun Bakım Ünitesi, İstanbul*
***İstanbul Memorial Hastanesi, Pediatrik Kardiyoloji Kliniği, İstanbul*

Özet

Son yıllarda konjenital aort stenozunun tedavisinde balon valvüloplasti giderek yaygınlaşmaktadır. Bu yöntemin aort kapakla ilgili komplikasyonları iyi bilinmekle beraber mitral kapak hasarı oldukça nadir görülmektedir. Bu yazıda 2 yıl önce uygulanmış aortik balon valvüloplasti işlemi sırasında mitral kapağın hasarlanması nedeni ile gelişen mitral yetersizliğin cerrahi olarak tedavi edildiği bir olgu incelenmiştir.

Anahtar kelimeler: Aort stenozu, perkütan balon valvotomi, mitral kapak hasarı

Summary

Türk Göğüs Kalp Damar Cer Derg 2005;13:169-170

In recent years balloon valvuloplasty has gained popularity for congenital aortic stenosis. Aortic complication of the procedure is well known whereas mitral valve injury is an exception. We report a case of surgically repaired mitral valve insufficiency, which was secondary to direct injury during aortic balloon valvuloplasty performed 2 years ago.

Keywords: Aortic stenosis, percutaneous balloon valvotomy, mitral valve damage

Turkish J Thorac Cardiovasc Surg 2005;13:169-170

Geliş Tarihi: Eylül 2002

Revizyon: -

Kabul Tarihi: 9 Şubat 2004

Introduction

Treatment of aortic stenosis in infants and neonates is still controversial. In recent years the balloon aortic valvuloplasty is widely accepted as an alternative to surgery because of its comparable early results [1]. Although several complications have been reported as aortic regurgitation or residual aortic gradient, mitral valve injury is very rarely described [2,3]. We report a case of surgically repaired mitral valve injury secondary to aortic balloon valvuloplasty performed in infancy.

Case

A 3-year-old boy was referred to our hospital for surgical repair of severe mitral valve regurgitation. He had a history of a percutaneous aortic balloon valvuloplasty for critical aortic stenosis in infancy. Progressive mitral valve regurgitation, which was absent before valvuloplasty procedure, was observed on routine echocardiographic follow-up. After 2 years of medical treatment the patient was referred to our clinic for

surgical repair.

His physical examination was unremarkable except an apical grade 3/6 and a grade 2/6 systolic murmur at the aortic area. Electrocardiography shows sinus rhythm with left ventricular hypertrophy. Moderate cardiomegaly was detected on telecardiography. Echocardiography revealed severe mitral valve regurgitation from a tear in the anterior leaflet and enlargement of the left side of the heart, mild aortic stenosis with 27 mm Hg gradient across the valve and mild aortic regurgitation.

The patient was undergone open-heart surgery with median sternotomy and standard cardiopulmonary bypass. Aorto – bicaval cannulation was used. After aortic clamp and isothermic blood cardioplegia, transseptal approach was used for mitral valve exposure. A cleft like tear on the middle of the anterior mitral leaflet with chordal elongation and annular dilatation was detected at surgery (Figure 1). The tear was repaired with interrupted pericardial pledgetted stitches and valve repair was completed with chordal plication and posterior annuloplasty. Perioperative transesophageal echocardiography revealed mild mitral regurgitation with 7 mm Hg mean gradient across the valve at the end of cardiopulmonary bypass.

Adres: Dr. Ece Salihoğlu, Acıbadem Bakırköy Hastanesi, Kalp Damar Cerrahisi Kliniği, İstanbul
e-mail: ecesalihoglu@anet.com.tr

The postoperative course was uneventful and the patient was discharged from hospital at postoperative day 6. The echocardiographic examination after 1 year postoperatively showed trivial or mild mitral regurgitation with mean transvalvular 5 mm Hg, and also mild aortic stenosis with 17 mm Hg systolic gradient and mild aortic regurgitation. He had NYHA class 1 functional capacity without medical treatment.

Discussion

Since the description of aortic balloon valvuloplasty, many studies compared the outcomes of surgical and catheter valvuloplasty techniques [1,4]. In recent years balloon valvuloplasty has gained popularity because of short hospitalisation period and good early results in congenital aortic stenosis [1,3,5]. Aortic complication of the procedure is well known whereas mitral valve injury is very rarely described, in all cases reported, this complication was related to posteriorly positioned guide wire in the left ventricle [2,3]. Brierly et al suggest that this malposition is more likely to occur if the patient has a small left ventricular cavity or an abnormal mitral apparatus. Reposition of the posteriorly positioned wire is necessary if it is noted on lateral screening or on transesophageal echocardiography during the procedure [2]. As in our case, none of the cases reported needed surgery immediately after balloon valvuloplasty [2,3]. It is possible, that the tear becomes excessive over time, or the blood turbulence across the damaged valve may cause secondary injury on other components of the mitral valve apparatus.

Many studies demonstrate that surgery for mitral valve can be performed with low risk in pediatric age group [6-8]. Plastic repair is the procedure of choice in children because of its several advantages like avoidance of thromboembolism, no need of long term anticoagulation, preservation of chordal function and a potentially reduced need for reoperation. Different surgical techniques have been used for mitral repair with good early and long-term results [6,8,9]. In this case we performed a successful combination of different techniques (primary repair of tear, chordal plication and annuloplasty) for mitral valve reconstruction.

As a conclusion, mitral injury during aortic balloon valvotomy is a rare complication. But this possible complication must be taken into account during the procedure and close follow up is necessary for eventual surgical repair. PABV procedure should be cautious in patients with small left ventricular cavity and mitral valve anomaly. Lateral screening and TEE may be helpful for proper positioning of the balloon. When mitral valve injury occurs, plastic repair should be performed without delay to prevent excessive degeneration of the valvular apparatus due to chronic blood turbulence across the valve and the left ventricular hypertrophy.

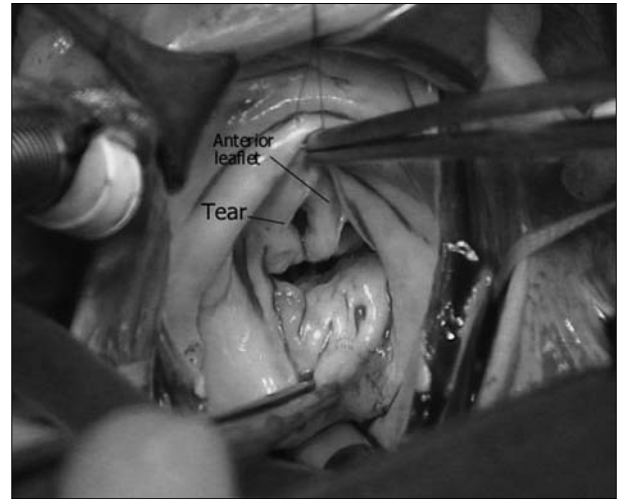


Figure 1. The tear on the anterior leaflet of the mitral valve

References

1. Mc Crindle BW, Blackstone EH, Williams WG, et al. Are outcomes of surgical versus transcatheter balloon valvotomy equivalent in neonatal critical aortic stenosis? *Circulation* 2001;104:152-8.
2. Brierly JJ, Reddy TD, Thanopoulos V, Redington AN. Traumatic damage to the mitral valve during percutaneous valvotomy for critical aortic stenosis. *Heart* 1998;79:200-2.
3. Sholler GF, Keane JF, Perry SB, et al. Balloon dilatation of congenital aortic valve stenosis: Results and influence of technical and morphological features on outcome. *Circulation* 1988; 78:351-60.
4. Hawkins JA, Minich LL, Llyod YT, et al. Late results and reintervention after aortic valvotomy for critical aortic stenosis in neonates and infants. *Ann Thorac Surg* 1998;65:1758-63.
5. Egito EST, Moore P, O'Sullivan J, et al. Transvascular balloon dilatation for neonatal critical aortic stenosis. *J Am Coll Cardiol* 1997;29:442-7.
6. Yoshimura N, Yamaguchi M, Oshima Y, et al. Surgery for mitral valve disease in the pediatric age group. *J Thorac Cardiovasc Surg* 1999;118:99-106.
7. Aharon AS, Laks H, Drinkwater DC, et al. Early and late results of mitral valve repair in children. *J Thorac Cardiovasc Surg* 1994;107:1262-71.
8. Ohno H, Imai Y, Terada M, Hisamatsu T. The long-term results of commissure plication annuloplasty for congenital mitral insufficiency. *Ann Thorac Surg* 1999;68:537-41.
9. Stellin C, Padalino M, Milanese O, et al. Repair of congenital mitral valve dysplasia in infants and children: Is it always possible? *Eur J Cardiothorac Surg* 2000;18:74-82.