

## Mobilization of the coronary artery in a patient with tetralogy of Fallot and abnormal coronary artery

*Fallot tetralojisi ve koroner arter anomalisi olan bir olguda koroner arterin serbestleştirilmesi*

**Ahmet Özkara,<sup>1</sup> Ali Kubilay Korkut,<sup>1</sup> Gürkan Çetin,<sup>1</sup> Murat Eranlı,<sup>2</sup> Kaya Süzer<sup>1</sup>**

Departments of <sup>1</sup>Cardiovascular Surgery and <sup>2</sup>Cardiology, İstanbul University Haseki Cardiology Institute, İstanbul

Surgical total correction of coronary artery anomalies in Fallot's tetralogy is associated with an increased risk for mortality and morbidity. Several techniques have been described for the reconstruction of the right ventricular outflow tract. We performed transannular patchplasty below the mobilized left anterior descending (LAD) coronary artery in a 31-year-old male patient in whom the LAD and the right coronary artery arose as a single ostium from the sinus 2. The LAD artery was mobilized together with the surrounding epicardium. The right ventricular outflow tract was reconstructed with the use of a pericardial patch beneath the LAD. The patient was discharged without any problem. This corrective technique is appropriate in adult patients with coronaries allowing dissection and mobilization without any stretch.

**Key Words:** Coronary vessel anomalies/surgery; pulmonary artery/surgery; tetralogy of Fallot/surgery.

Koroner arter anomalisi, Fallot tetralojisinin cerrahi olarak tam düzeltilmesinde mortalite ve morbiditeyi artıran bir faktördür. Sağ ventrikül çıkış yolu rekonstrüksiyonunda farklı cerrahi teknikler tarif edilmiştir. Sol ön inen (LAD) koroner arter ile sağ koroner arterin sinus 2'den tek bir ostium şeklinde çıktığı 31 yaşındaki bir erkek hastada, sol ön inen arter serbestleştirildikten sonra, koroner arterin altından transannuler patchplasti yöntemi uygulandı. Sol ön inen arter, etrafındaki epikard dokusu ile birlikte serbestleştirildi. Sağ ventrikül çıkış yolu, LAD'nin altına yerleştirilen perikard yama ile genişletildi. Hastada ameliyat sonrası dönemde herhangi bir sorun olmadı. Bu cerrahi teknik, koroner arterin gerginliğe yol açmadan mobilize edilebileceği erişkin hastalar için uygundur.

**Anahtar sözcükler:** Koroner damar anomalisi/cerrahi; pulmoner arter/cerrahi; Fallot tetralojisi/cerrahi.

The incidence of coronary artery anomalies is 2% to 10% in patients with Fallot's tetralogy.<sup>[1]</sup> Surgical approach in patients having one coronary artery crossing the obstructed and hypoplastic right ventricular outflow tract (RVOT) is challenging and associated with increased operative mortality and morbidity.<sup>[2]</sup> Preoperative recognition of coronary artery anomalies is essential for an appropriate surgical technique. Echocardiographic assessment and coronary angiography are the most useful techniques to visualize the coronary artery crossing the RVOT.<sup>[3]</sup> Various techniques have been described to establish the continuity between the right ventricle and the pulmonary artery.<sup>[4]</sup> The type of surgical reconstruction is individualized depending on both the anatomy of the RVOT and the course of the coronary artery over the RVOT. Techniques for RVOT reconstruction include an oblique ventriculotomy, tailored ventriculotomy, two-patch repair, translocation of the main pulmonary artery, transannular repair below a mobilized coronary artery, and pulmonary homograft conduit.<sup>[4]</sup>

We performed transannular patchplasty below the mobilized left anterior descending coronary artery in an adult patient. This corrective technique is appropriate in adult patients with coronaries allowing dissection and mobilization without any stretch.

### CASE REPORT

A 31-year-old man was admitted to our institute with symptoms of reduced effort capacity (NYHA class II) and mild cyanosis. There was a systolic murmur of 3/6 degree on the left side of the sternum. A perimembranous-outlet ventricular septal defect (VSD), dextraposition of the aorta, and a 79-mmHg gradient across the RVOT were determined on echocardiography. The right and the left pulmonary arteries measured 15 mm and 18 mm, respectively, and the McGoon index was greater than 2. Cardiac catheterization showed that the left anterior descending (LAD) artery and the right coronary artery arose together as a single ostium from the sinus 2 (Fig. 1a), and the circumflex artery from the sinus 1.

Received: August 2, 2004 Accepted: December 3, 2004

Correspondence: Dr. Ali Kubilay Korkut, İstanbul Üniversitesi Haseki Kardiyoloji Enstitüsü, Kalp ve Damar Cerrahisi Anabilim Dalı, 34087 İstanbul. Tel: 0212 - 661 33 04 e-mail: kubilaykorkut@superonline.com

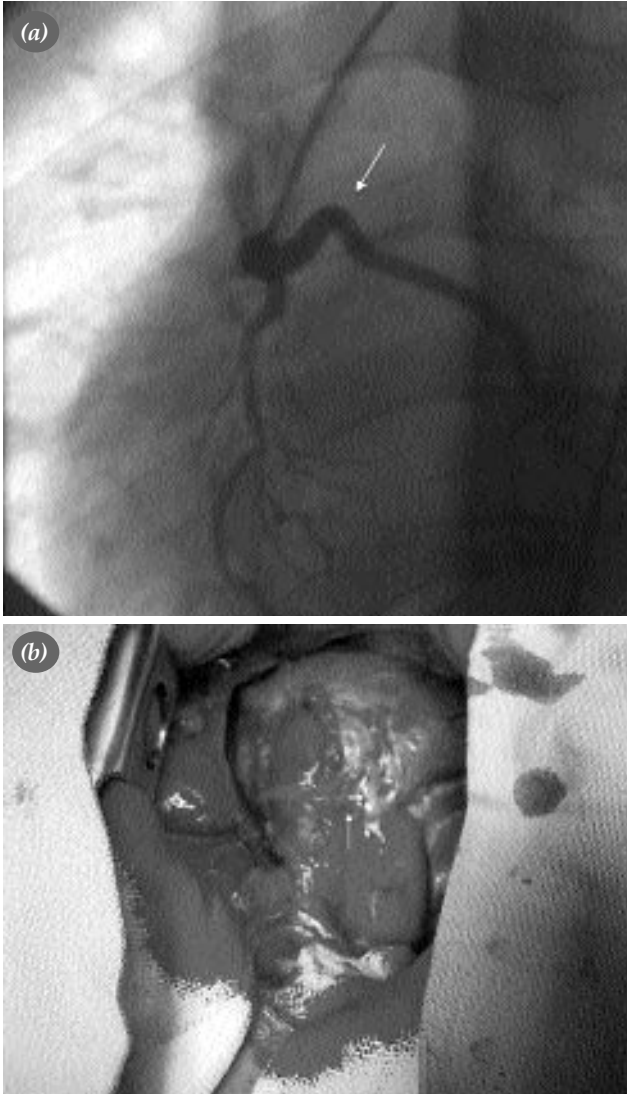
**Surgical technique.** After a median sternotomy, a pericardial patch was prepared and treated with 0.9% gluteraldehyde solution. Surgical exploration confirmed that the LAD and the right coronary artery arose as a single ostium from the sinus 2. The LAD artery then crossed over the muscular wall and gave small perforating conal branches. The left internal thoracic artery (LITA) was prepared without cutting the distal end. Cardiopulmonary bypass was performed with aortic, vena cava superior and inferior cannulation. Myocardial preservation was achieved with antegrade blood cardioplegia repeated in every 20 minutes. A large VSD of 2 cm diameter was closed using a Dacron patch with separate pledged sutures through a

RVOT incision which provided better exposure than that made through the right atrium. The LAD artery was mobilized together with the surrounding epicardium so that the RVOT patch provided a pulmonary annulus 20 mm in diameter beneath the mobilized LAD artery. The patch was 2 cm in width. Some small conal branches were cut during LAD dissection. Reconstruction of the RVOT was performed with a pericardial patch with the use of running polypropylene sutures. The right atrium was closed and the cross-clamp was removed. The LAD artery crossing over the RVOT patch is shown in Fig. 1b.

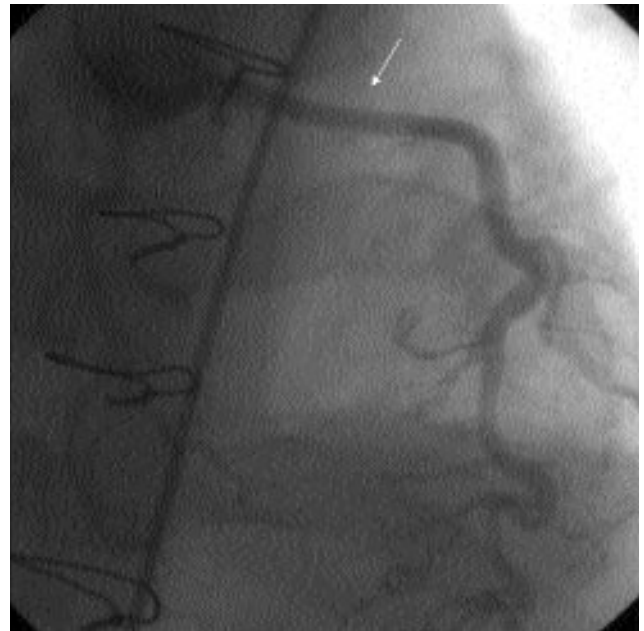Aortic, right ventricular, and pulmonary artery pressures were 130/60 mmHg, 60/4 mmHg, and 25/12 mmHg, respectively. The patient was extubated after six hours and discharged on the tenth postoperative day without any complication. The postoperative course of the LAD artery is seen on a control angiogram in Fig. 2.

## DISCUSSION

The diagnosis and correction of Fallot's tetralogy are usually made in infancy or in early childhood. A transannular vertical incision followed by patchplasty is the most preferred approach in patients with a normal coronary arterial pattern.<sup>[5]</sup> However, in cases with a major coronary artery crossing the RVOT, a different surgical technique should be employed. In these cases, an oblique ventriculotomy, tailored ventriculotomy, two-patch repair, interposing of an extracardiac pulmonary homograft conduit are frequently used approaches.<sup>[4]</sup>



**Fig. 1. (a)** The left anterior descending (LAD) artery arose as a single ostium together with the right coronary artery (RCA). The tortuous segment of the LAD is observed over the right ventricular outflow tract (RVOT) area. **(b)** The white arrow indicates the LAD artery crossing over the RVOT patch.



**Fig. 2.** A control angiogram showing the disappearance of the tortuous segment of the LAD after RVOT patchplasty.

Mobilization of the crossing coronary artery along the RVOT and placement of a transannular patch below the mobilized coronary artery is another technique described by Bonchek.<sup>[6]</sup> The coronary artery should allow dissection and elongation above the patch without any stretch. In our patient, the LAD artery had a tortuous segment proximally, which allowed elongation of the LAD without coronary arterial malperfusion. Although Tchervenkov et al.<sup>[4]</sup> reported successful mobilization of the coronary arteries in children, this seems to be more securely used in adult patients due to the possibility of spasm of the coronary artery in children.

If any ischemic problem occurs when using any type of these techniques, anastomosis of the LITA to the coronary artery should be performed. In these patients, the LITA should be harvested without cutting the distal end. Moreover, this anastomosis should be performed promptly in case of myocardial ischemia and systolic dysfunction following cessation of cardiopulmonary bypass.

Extracardiac pulmonary conduit replacement may be an alternative method. However, the probability of reoperation for conduit replacement and the risk for ischemia due to compression of the coronary artery by the conduit are major disadvantages of this technique.<sup>[2]</sup>

In conclusion, there are several reconstruction techniques in adult patients with the LAD artery crossing

the RVOT. Transannular patchplasty beneath the LAD is appropriate in patients in whom the LAD artery is tortuous and allows dissection along the width of the patch without any stretch. Furthermore, the risk for a reoperation is lower. However, this technique should not be considered in children and neonates whose coronary arteries are very small in diameter and inappropriate for elongation.

## REFERENCES

1. Hurwitz RA, Smith W, King H, Girod DA, Caldwell RL. Tetralogy of Fallot with abnormal coronary artery: 1967 to 1977. *J Thorac Cardiovasc Surg* 1980;80:129-34.
2. Humes RA, Driscoll DJ, Danielson GK, Puga FJ. Tetralogy of Fallot with anomalous origin of left anterior descending coronary artery. Surgical options. *J Thorac Cardiovasc Surg* 1987;94:784-7.
3. O'Sullivan J, Bain H, Hunter S, Wren C. End-on aortogram: improved identification of important coronary artery anomalies in tetralogy of Fallot. *Br Heart J* 1994;71:102-6.
4. Tchervenkov CI, Pelletier MP, Shum-Tim D, Beland MJ, Rohlicek C. Primary repair minimizing the use of conduits in neonates and infants with tetralogy or double-outlet right ventricle and anomalous coronary arteries. *J Thorac Cardiovasc Surg* 2000;119:314-23.
5. Hallman GL, Cooley DA. Surgical treatment of tetralogy of Fallot: experience with indirect techniques. *J Thorac Cardiovasc Surg* 1963;46:419-23.
6. Bonchek LI. A method of outflow tract reconstruction in tetralogy of Fallot with anomalous anterior descending coronary artery. *Ann Thorac Surg* 1976;21:451-3.